



Acquired Diseases of the Macula

BOARD REVIEW

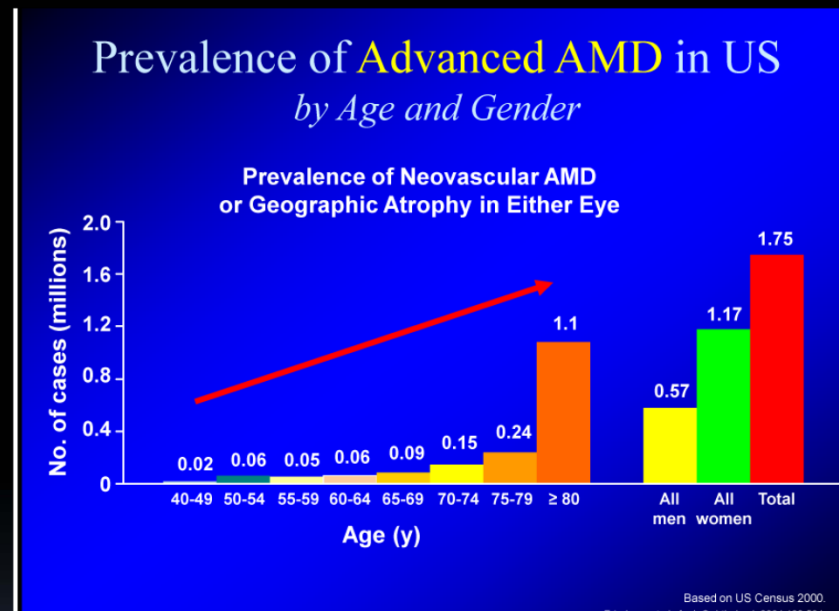


ANNA GABRIELIAN, MD
JANUARY 9, 2014

NO FINANCIAL DISCLOSURES

AMD Prevalence

- AMD is the most common cause of irreversible legal blindness in patients > 65 years old
- Incidence in vision loss increases with age
 - 30% patients 75years old will have some sign of macular degeneration



AMD Risk Factors – Demographics

- Advancing Age
- Sex – Females
 - Higher kinase insert domain receptors for VEGF?
- Race – Less pigmented
 - Melanin lowers oxidation damage by decreasing RPE lipofuscin?

AMD Risk Factors - Cardiovascular

- Cigarette smoking
 - Nicotine increases endothelial cell proliferation
- Hypertension
 - Angiotensin II induces expression of VEGF and angiopoietin 2

AMD Risk Factors – Lifestyle

- Light Exposure
 - Years of UV exposure – increased oxidation; lipid peroxidation in OS (higher proportion of PUFA)
 - Lipofuscin increases with age and increases auto-oxidation
- Diet
 - AMD increased with high fat, high cholesterol diet
 - AMD lowered by high Zn, vitamin E, B-carotene, Lutein, & Zeaxanthine

AREDS

(Age related eye disease study, 2001)



- Enrolled 4757 patients at 11 clinical centers and evaluated the effect of high-dose micronutrient supplements on AMD and vision loss.
 - Vitamin C 500 mg
 - Vitamin E 400 IU
 - Vitamin A (Beta Carotene) 15 mg
 - Zinc & Copper (80 mg zinc oxide and 2 mg cupric oxide to prevent zinc-induced anemia)

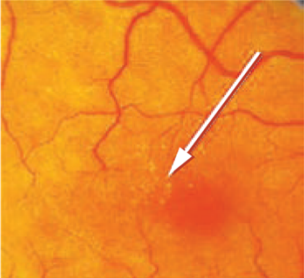
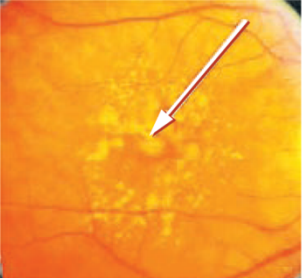
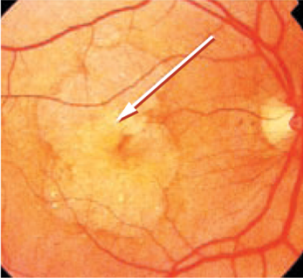
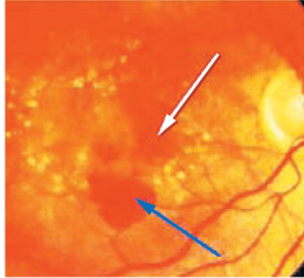
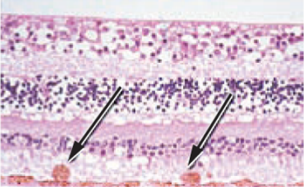
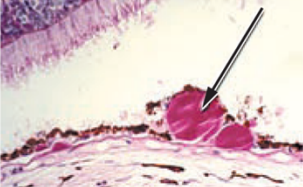
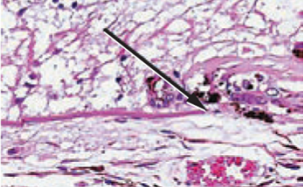
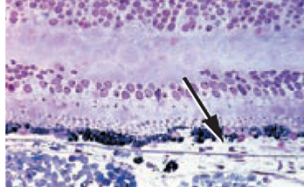
AREDS

(Age related eye disease study)



■ Results

- Individuals with
 - Intermediate AMD (extensive intermediate or at least 1 large druse, or nonsubfoveal geographic atrophy)
 - Advanced unilateral AMD (vision loss due to AMD in 1 eye)
- 25% reduction of risk for progression to advanced AMD
- 19% risk reduction in rates of moderate vision loss (≥ 3 lines of visual acuity) by 5 years
- Subjects with no AMD or only early AMD (few small drusen) did not derive any benefit.

	A Early AMD	B Intermediate AMD	C Advanced Non-neovascular AMD	D Advanced Neovascular AMD
Fundus				
Histopathological Features				
Clinical Features	<p>Presence of a few medium-size drusen</p> <p>Pigmentary abnormalities such as hyperpigmentation or hypopigmentation</p>	<p>Presence of at least one large druse</p> <p>Numerous medium-size drusen</p> <p>Geographic atrophy that does not extend to the center of the macula</p>	<p>Drusen and geographic atrophy extending to the center of the macula</p>	<p>Choroidal neovascularization and any of its potential sequelae, including subretinal fluid, lipid deposition, hemorrhage, retinal pigment epithelium detachment and a fibrotic scar</p>
Current Management	<p>Lifestyle and dietary modifications (e.g., cessation of tobacco use, increased dietary intake of antioxidants, control of blood pressure and body-mass index)</p>	<p>Supplementation according to the Age-Related Eye Disease Study</p> <p>Lifestyle and dietary modifications</p>	<p>Supplementation according to the Age-Related Eye Disease Study, if the other eye has early or intermediate AMD</p> <p>Lifestyle and dietary modifications</p>	<p>Supplementation according to the Age-Related Eye Disease Study, if the other eye has early or intermediate AMD</p> <p>Lifestyle and dietary modifications</p> <p>Antiangiogenic therapy (e.g., intravitreal injection of antiangiogenic or angiostatic agents)</p> <p>Laser therapy (ocular photodynamic therapy or argon-laser photocoagulation)</p>

AREDS Applications

- Risk factors for developing advanced AMD
 - Presence of one or more large drusen (1 point)
 - Presence of any pigment abnormalities (1 point)
 - For patients with no large drusen, presence of bilateral intermediate drusen (1 point)
 - Presence of neovascular AMD (2 points)

Risk factors for developing advanced AMD

	5-Year Risk	10-Year Risk
0 factors	0.5%	1%
1 factor	3%	7%
2 factors	12%	22%
3 factors	25%	50%
4 factors	50%	67%

AREDS Recommendations

- Give supplements to patients with high risk including
 - Extensive intermediate drusen
 - At least 1 large druse
 - Non-central geographic atrophy
 - Advanced AMD in 1 eye
- For smokers avoid supplementation with beta carotene (15 mg.)
 - Higher incidence of lung cancer (including on patients with pulmonary asbestos)

AREDS II



- Studied the effects of supplementing on:
advanced AMD, cataract and moderate
vision loss
 - Lutein 10 mg
 - Zeaxanthin 2 mg
 - Omega-3 Long chain fatty acids
 - Reduce Zinc to 25 mg (from 80 mg)

AREDS II Results



- No overall additional benefit from adding omega-3 fatty acids, lutein and zeaxanthin to the formulation, unless patients had very little lutein and zeaxanthin in their diets.
 - 25% less likely to develop advanced AMD compared with participants with similar dietary intake who did not take lutein and zeaxanthin
- AREDS formulation with lutein and zeaxanthin but no beta-carotene, reduced risk of developing advanced AMD over the five years by 18%, compared with participants who took an AREDS formulation with beta-carotene but no lutein or zeaxanthin
 - Removing beta-carotene from the AREDS formulation did not curb the formulation's protective effect against developing advanced AMD
- No protective effect on cataract progression

AMD Etiology - Genetics

- Family history
 - First degree relative increases risk 3X
 - Monozygotic twins 90% concordance
- Genetics
 - 50% of AMD could be single gene
 - Abetalipoprotein E2 allele increases risk of CNV by 50%
 - ABCR gene (Stargardt) seen in dry AMD
 - Complement Factor H

AMD Etiology - Genetics

- Complement Factor H
 - Involved in complement fixation pathway
 - Responds to inflammation
 - Presence of allele seen in 20-30% of normal population vs. >45% in AMD
 - 1 allele – increases CNV risk 3X
 - 2 alleles – increase CNV risk 7X

AMD Etiology – Hydrodynamic

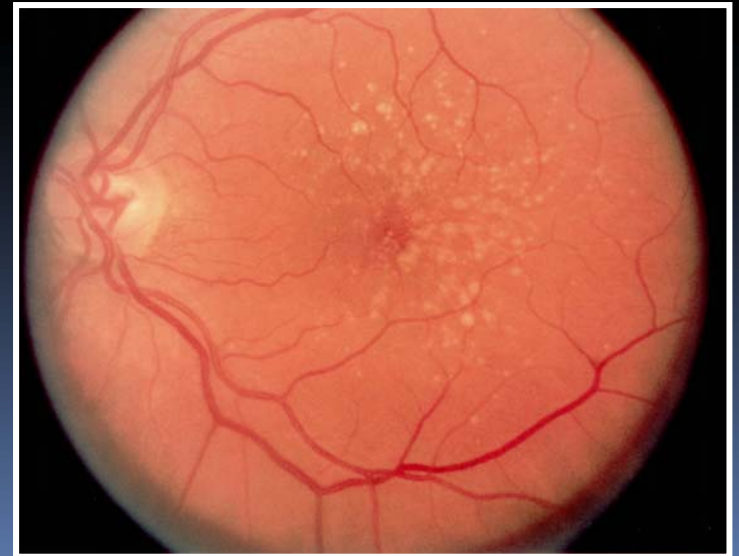
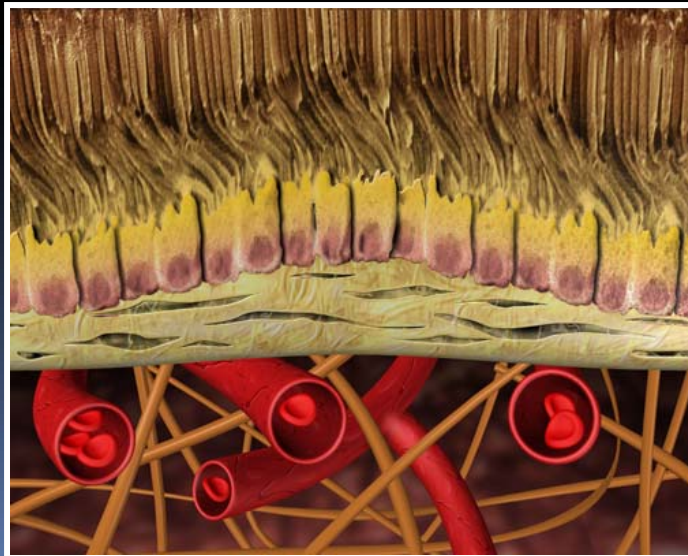
- Bruch's membrane increases in lipid content & thickens 135% with age
- Choriocapillaris density decreases 45% and choroidal blood flow slows with age
- Net result: less diffusion of nutrients to RPE
- Watershed areas of poor flow create RPE mottling & hyperpigmentation
 - CNV grows in these areas

RPE

- Loses ability to grow with age
- Loses lysosomal activity to degrade and shed segments
- Accumulates lipofuscin
- Secretes less PEDG (pigment epithelial derived factor), which is anti-angiogenic

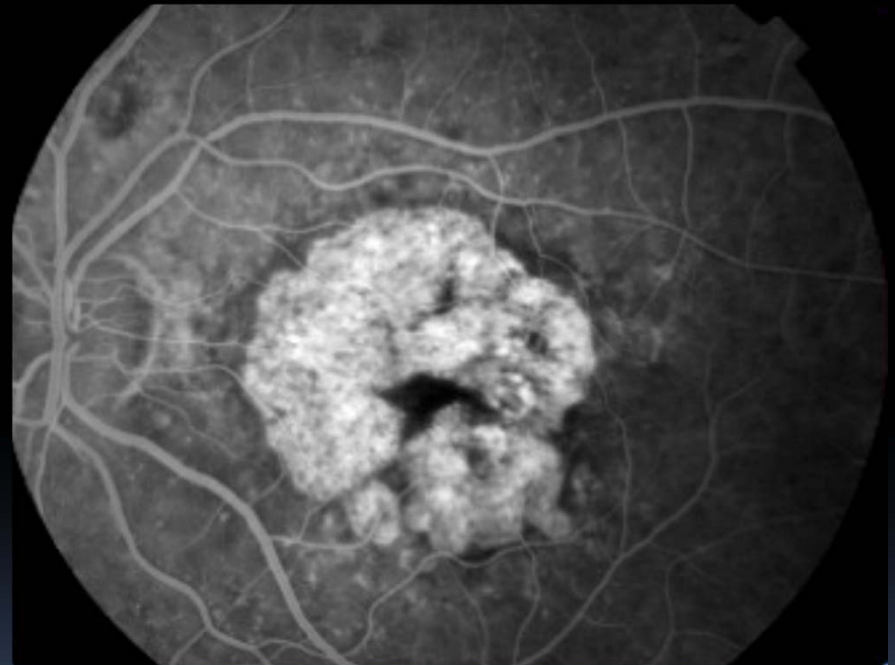
AMD Hallmark: Drusen

- Most common between temporal vascular arcades
- Large, confluent drusen have higher risk of visual loss from exudative change
- Can coalesce into serous RPE detachments



Non-Exudative AMD (>70%)

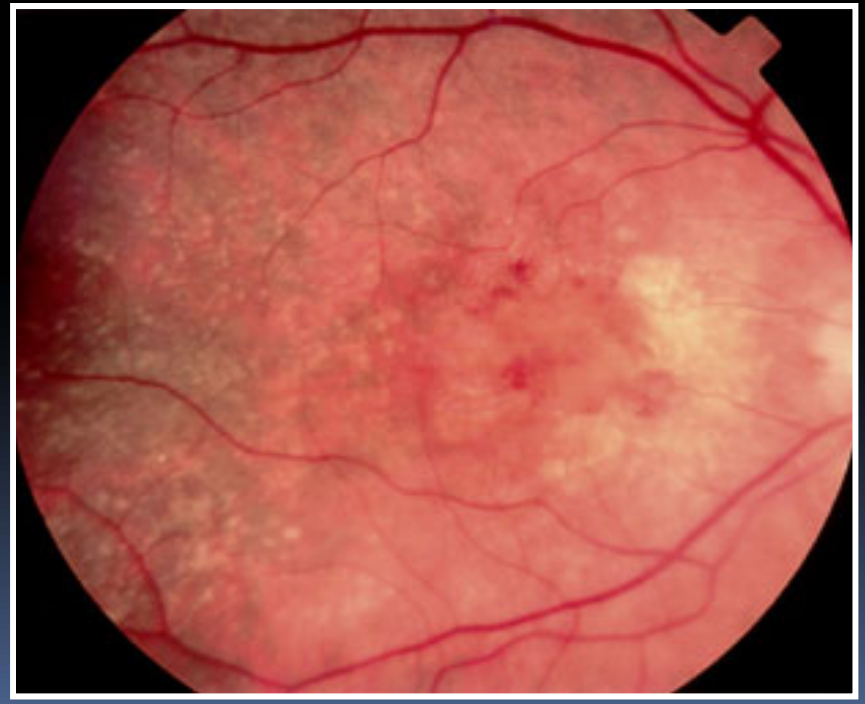
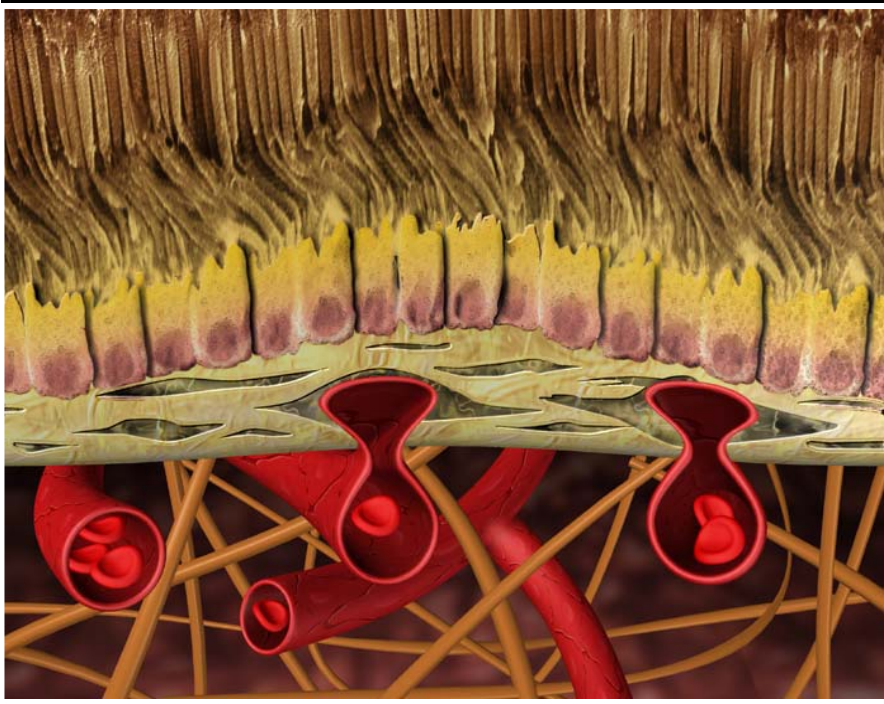
- RPE mottling
- Geographic atrophy
 - RPE and choriocapillaris
 - Is the most likely change in dry AMD to be symptomatic
 - Borders expand over time (lights in AF)
 - Considered end stage dry AMD



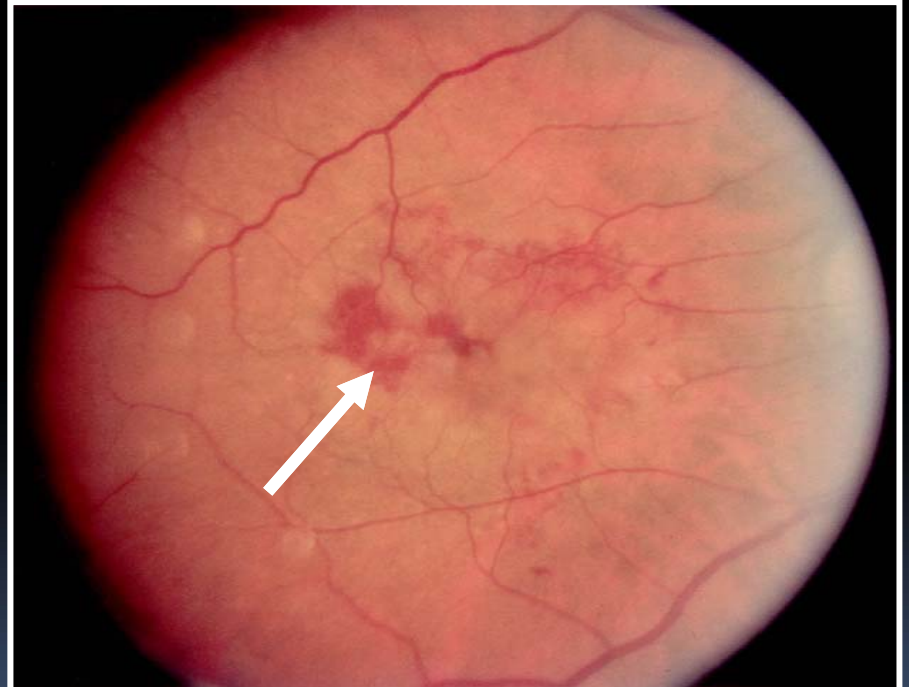
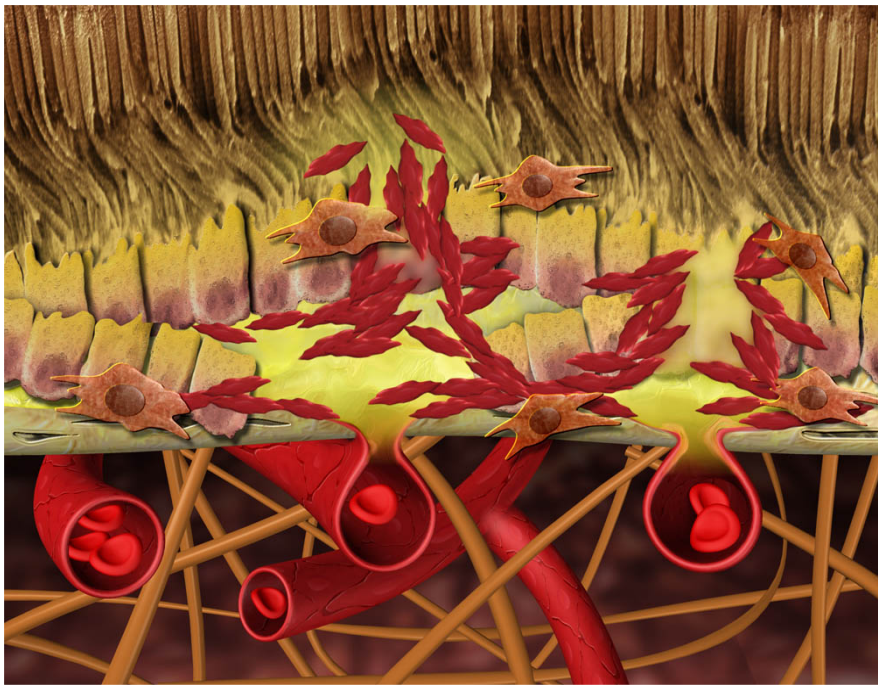
DDx for Non-Neovascular AMD

- Resolved central serous chorioretinopathy
- Pattern Dystrophy
- Cuticular Drusen
- Drug toxicity

Progression to Neovascular AMD - Formation of New Vessels



Progression of Neovascular AMD - Leakage of Fluid and Blood from CNV



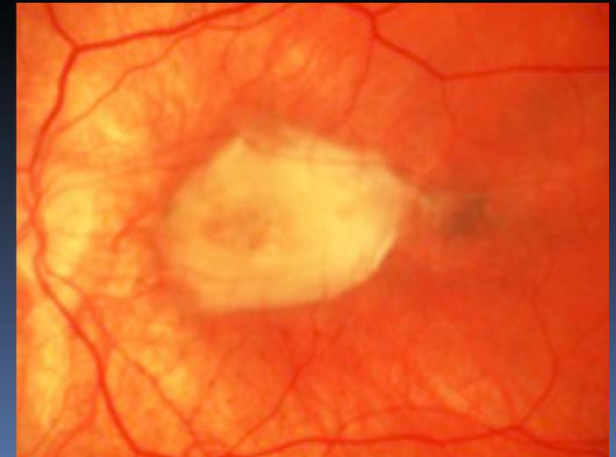Neovascular AMD & VEGF

(vascular endothelial growth factor)

- VEGF secreted by RPE, accumulates in vascular endothelial cells of AMD patients
- In response to ischemia
- Induced by signaling molecules
- Affects
 - Vascular permeability
 - Endothelial cell permeability
 - Endothelial cell survival
 - Inflammatory cell chemotaxis

Features of Neovascular AMD

- A combination of serous fluid, hemorrhage and lipid exudates (which can be found in all layers)
 - Sub-RPE, sub-retinal, intra-retinal, pre-retinal, intravitreal
 - RPE tears (poor prognostic factor)
 - Disciform scar is considered end-stage



Diagnostic Testing for AMD

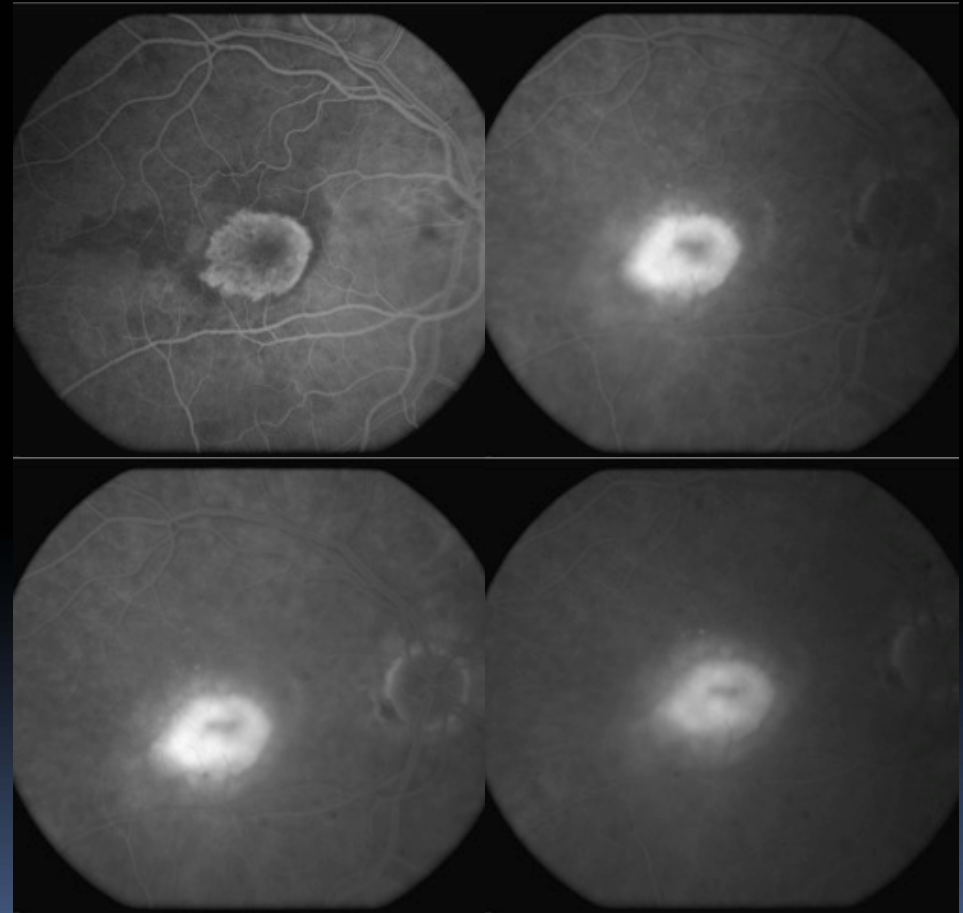
- Fluorescein angiogram still the gold standard
 - ICG more helpful if occult membrane is suspected or when there is blood blocking
- OCT
- Autofluorescence

Classic vs. Occult Distinction

- Important when treatment is going to be based on laser or PDT
- Not as important with anti-VEGF agent use

Classic CNV on Fluorescein Angiogram

- Bright, fairly uniform hyperfluorescence in the early phase
- Progressively intensifies thru the transit phase
- Leakage of dye obscures the boundaries of this area by the late phases

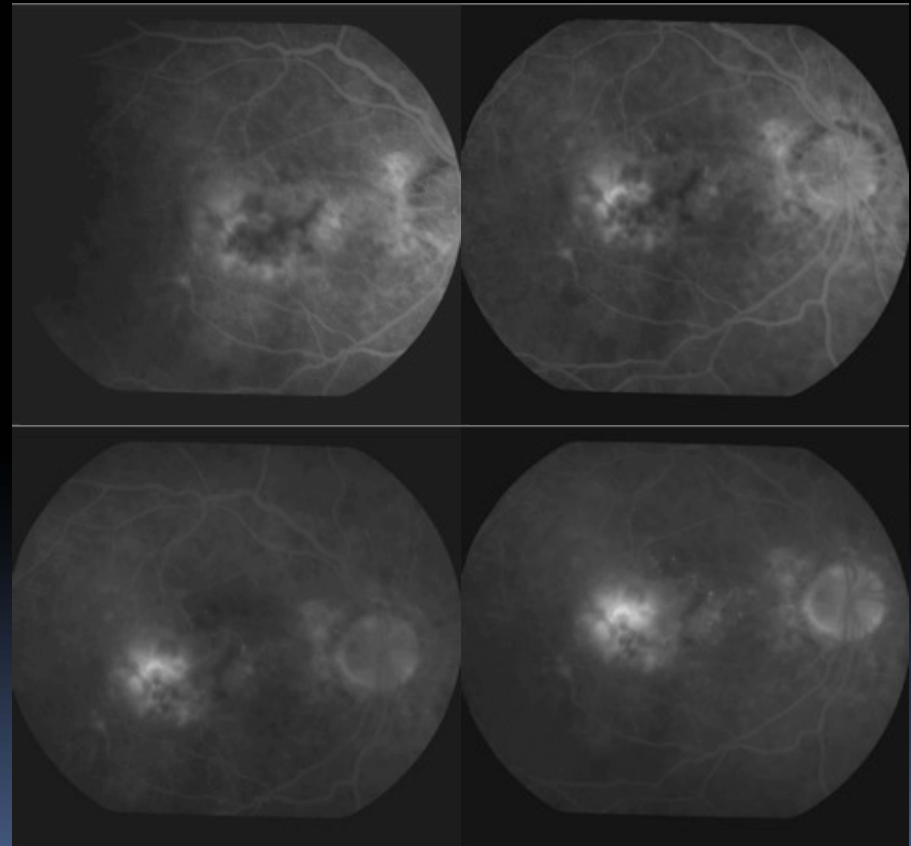


Occult CNV on FA

- Consists of 2 forms:
 - Fibrovascular PED
 - Late leakage from an undetermined source

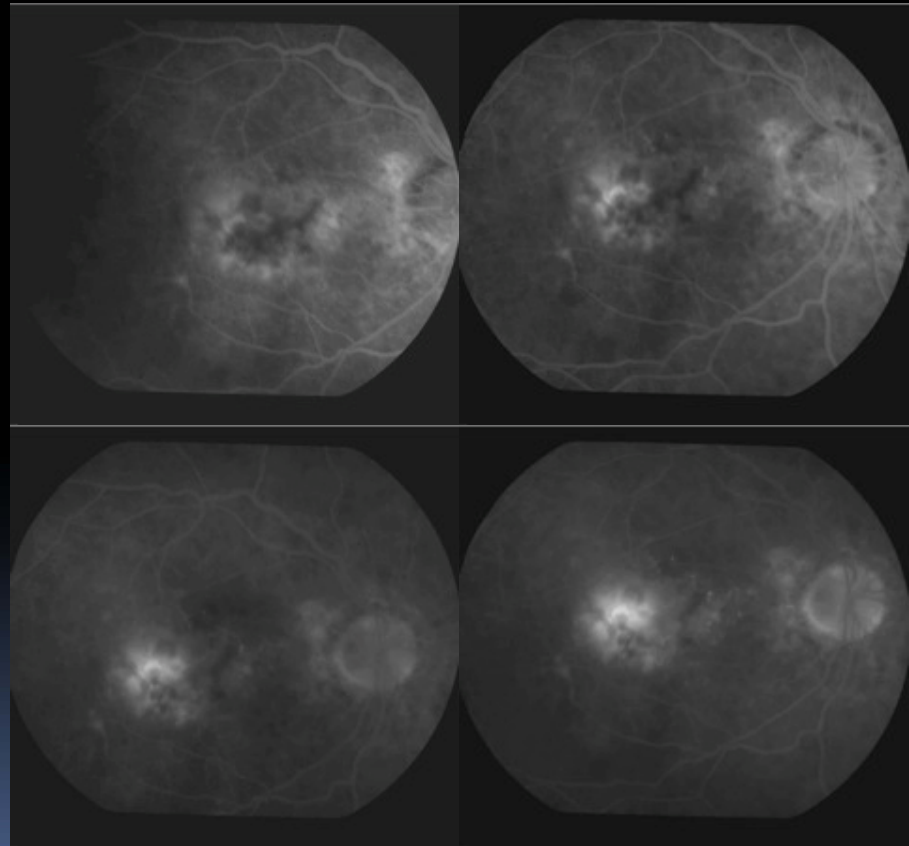
Occult CNV on FA

- Fibrovascular PED
 - irregular elevation of the RPE with granular irregular fluorescence
 - no specific borders early or late on the angiogram

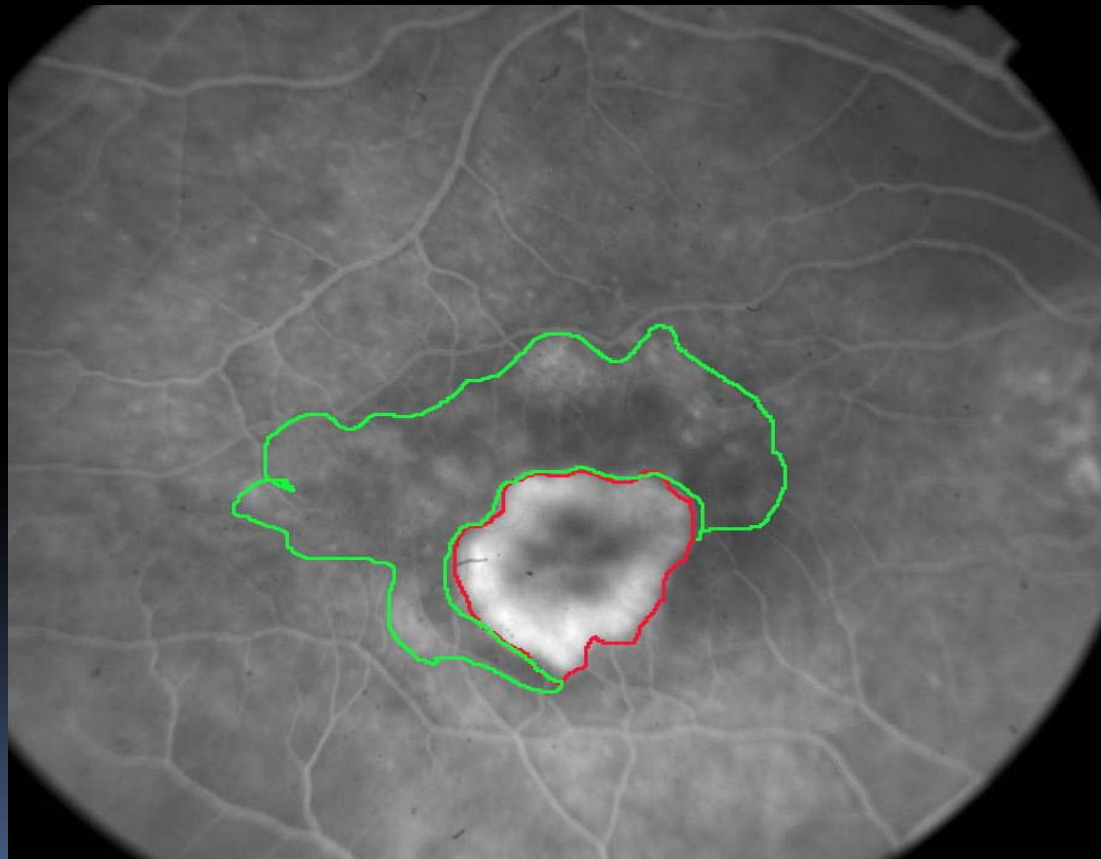


Occult CNV on FA

- Late leakage (from undetermined source)
 - Regions of fluorescence (RPE level), best appreciated in late phases



Combined Classic with Occult CNV



DDx of Neovascular AMD

- Polypoidal Choroidal Vasculopathy
- Central Serous Chorioretinopathy
- Macular Telangiectasis
- Myopic Degeneration with CNV

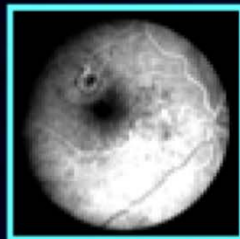
Neovascular AMD Treatments

- Historically
 - MPS (Macular Photocoagulation Study) Trials
 - Surgical resection
 - PDT
- Currently
 - Anti-VEGF Agents
 - VEGF-Trap

MPS

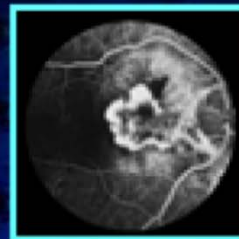
The **MPS** Trials: **M**acular **P**hotocoagulation **S**tudy
Three Diseases: 1. AMD 2. POHS 3. Idiopathic CNV

ARGON STUDY



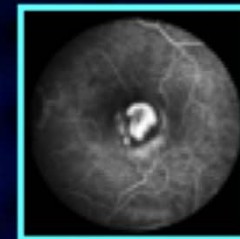Extrafoveal CNV

KRYPTON STUDY



Juxtafoveal CNV

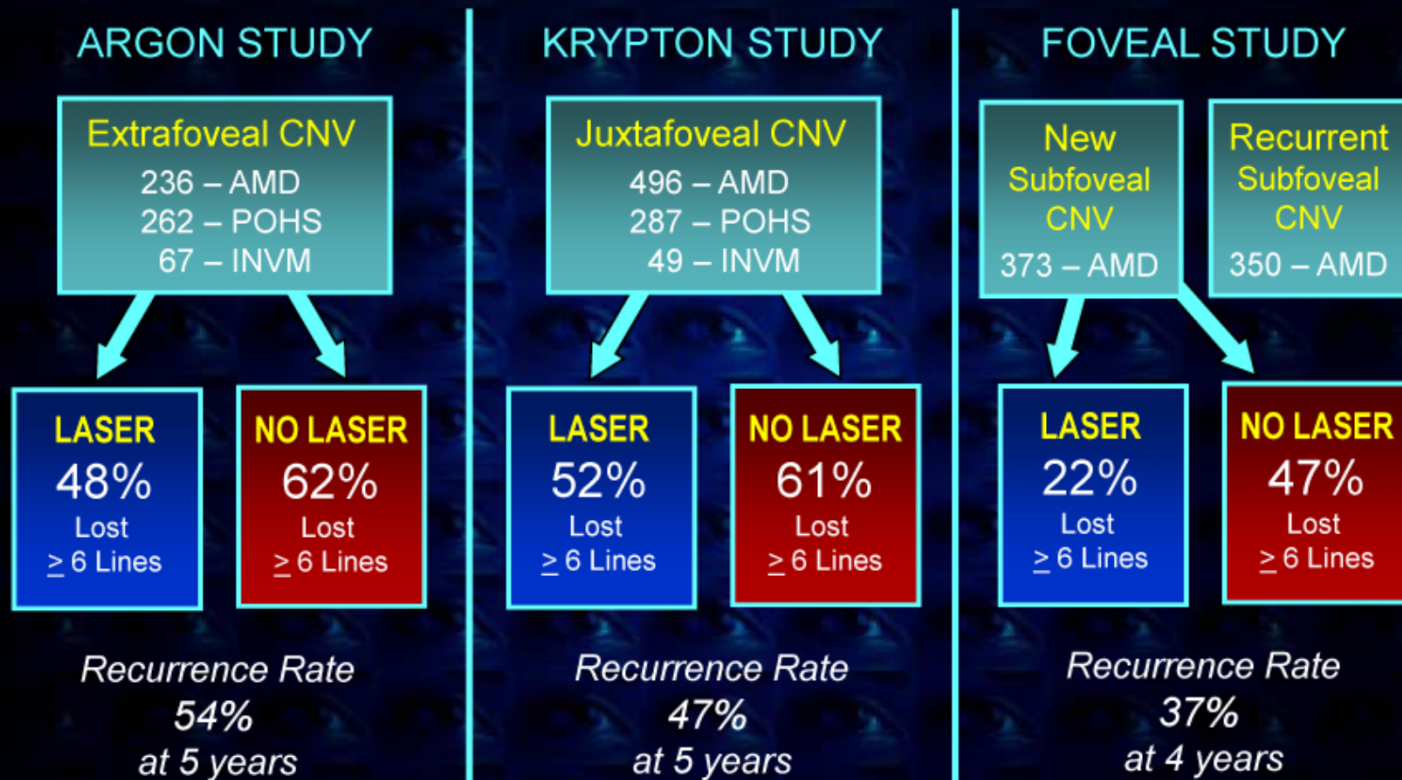
FOVEAL STUDY



Subfoveal CNV

The MPS Trials: Macular Photocoagulation Study

Three Diseases: 1. AMD 2. POHS 3. Idiopathic CNV



- Complications
 - High recurrence rate
 - Enlarging laser scars
 - Laser induced CNV (break in Bruch's)
 - Epiretinal and subretinal fibrosis
 - RPE tear

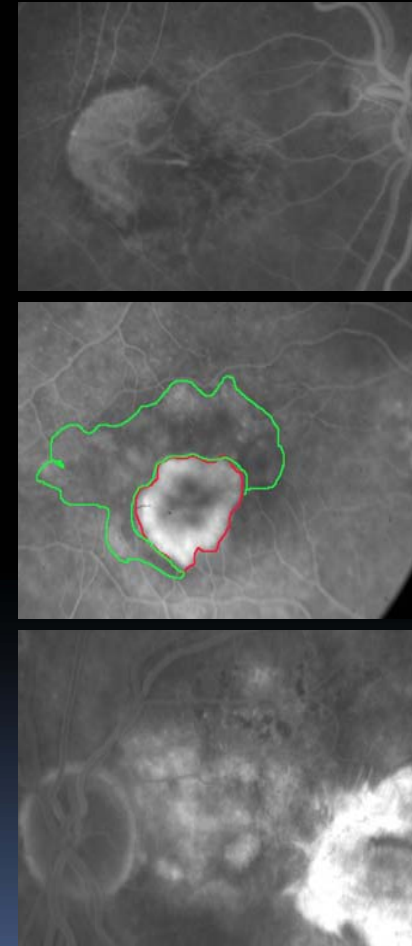
PDT

- Photodynamic Therapy (PDT, cold laser), Verteporfin (Visudyne)
 - 2 step process
 - Verteporfin injection IV, accumulated on serum LDL (CNV has high LDL receptor accumulation)
 - Verteporfin is activated by cold laser
 - Produces reactive oxygen products
 - Endothelial cell damage, thrombosis and CNV closure



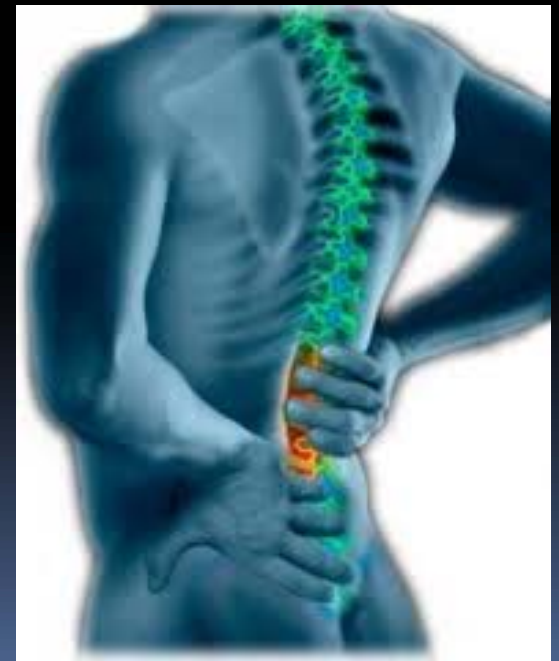PDT

- PDT effectiveness is dependent of CNV type by FA
 - Most effective
 - Classic pattern (TAP study)
 - Effective
 - Minimally classic (VIM study)
 - Less effective
 - Occult with no classic (VIP study)



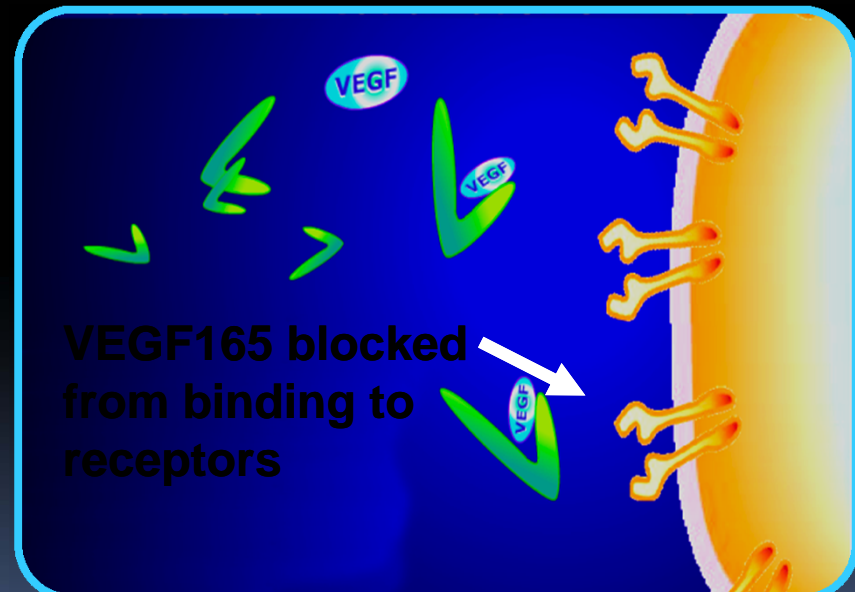
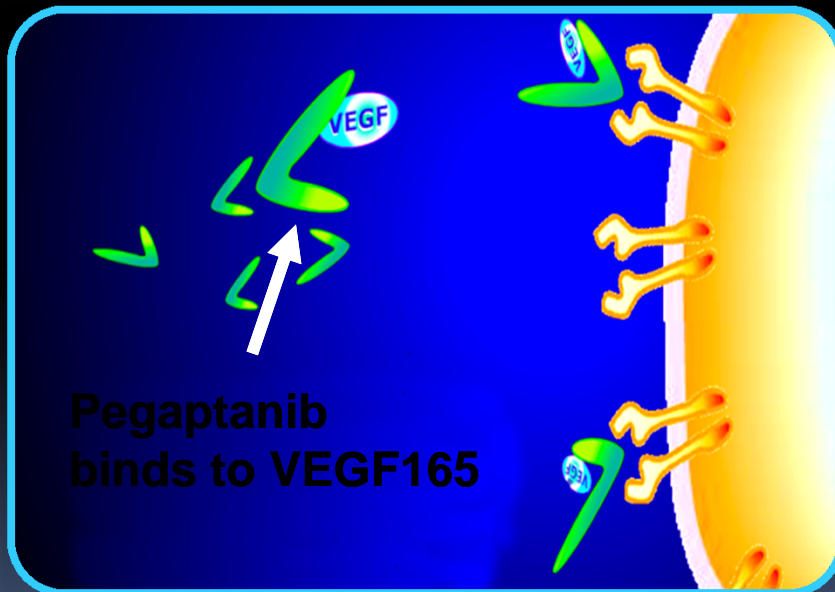
PDT

- PDT can produce
 - Ischemia/atrophy of RPE and photoreceptors
 - Loss of contrast sensitivity
 - Upregulation of VEGF
 - 90% recurrence within 3 months
 - Dermal photosensitivity to UV
 - 5 days post injection
 - Lower back pain at infusion time
 - Vision loss after treatment
 - Occlusion of choriocapillaris



Pegaptanib Clinical Trials

The First Anti-VEGF Therapy for AMD



Pegaptanib Clinical Trials

The First Anti-VEGF Therapy for AMD

- Macugen as a history maker
 - First approved AMD drug therapy
 - First human aptameric therapy
 - Aptamer (not Ab) for VEGF 165
 - The largest clinical trial (VISION) performed for AMD to that point
 - Only 28% had no progression
 - Vision improved in only 6%
 - The start of the “Injection Therapy”

Ranibizumab (Lucentis™) Studies



1. ANCHOR Study

ANti-VEGF Antibody for the Treatment of Predominantly Classic CHORoidal Neovascularization in AMD

2. MARINA Study

Minimally Classic/Occult Trial of the ANti-VEGF Antibody Ranibizumab IN the Treatment of Neovascular AMD

3. FOCUS Study

RhuFab V2 Ocular Treatment Combining the Use of Visudyne™ to Evaluate Safety

4. PIER Study

Phase IIIb, Multicenter, Randomized, Double-Masked Sham Injection-Controlled Study of Efficacy of Ranibizumab

5. SAILOR Study

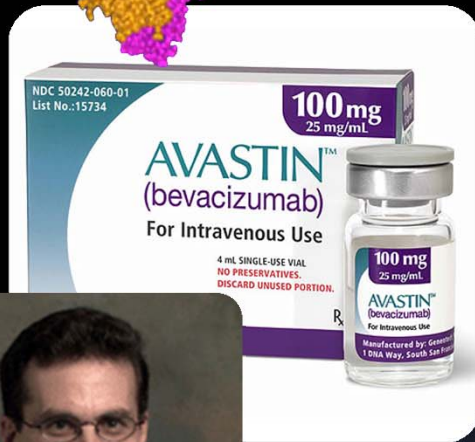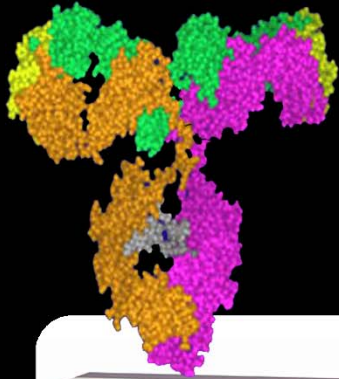
Safety Assessment of Intravitreal Lucentis fOR AMD

Ranibizumab (Lucentis™) Studies

- Lucentis (ranibizumab)
 - FDA approved in 2006
 - First treatment to target improvement of vision
 - Is a pan-isoform Ab (binds to all VEGF group A) receptors
 - 95% pts with vision loss prevention
 - 33% pts with visual gain

Bevacizumab (Avastin™)

“Full” Antibody



*Philip
Rosenfeld, MD PhD*

- IV infusion for colon cancer
- IV infusion for AMD initially studied at Bascom Palmer
- Intraocular injection studied by Rosenfeld and Avery
- Currently used by most retina specialists in US (>70%)

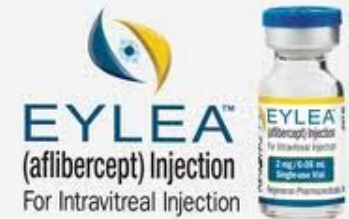

 National Eye Institute


CATT trial (Comparison of AMD Treatment Trials)

- The purpose of the study was to evaluate the efficacy and safety of treatment of neovascular AMD with
 - Lucentis and Avastin on a fixed vs. variable schedules
 - At 2 years, bevacizumab and ranibizumab had equivalent effects on visual acuity
 - PRN treatment resulted in less VA gain
 - No difference in the rates of death or arteriothrombotic events
 - Slightly more systemic adverse effects with bevacizumab

VEGF-Trap

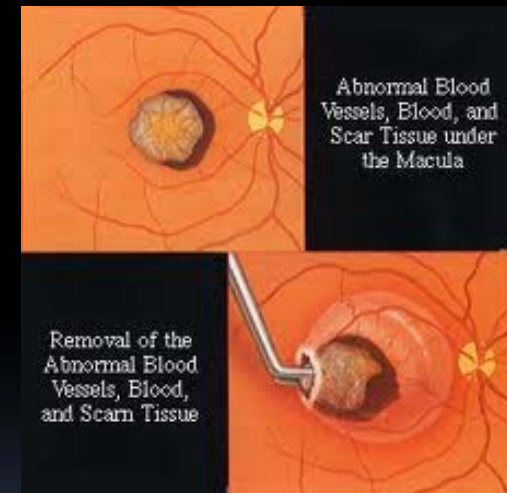


- Eylea (aflibercept)
 - Selectively binds and neutralizes all exogenous VEGF-A molecular isoforms, and placental growth factor
 - Functions as a potent decoy receptor, binding VEGF more tightly than either native receptors or monoclonal antibodies
 - Latest data shows that it's superior:
 - 1) in achieving complete dryness on OCT
 - 2) for patients with persistent fluid
 - 3) for PEDs



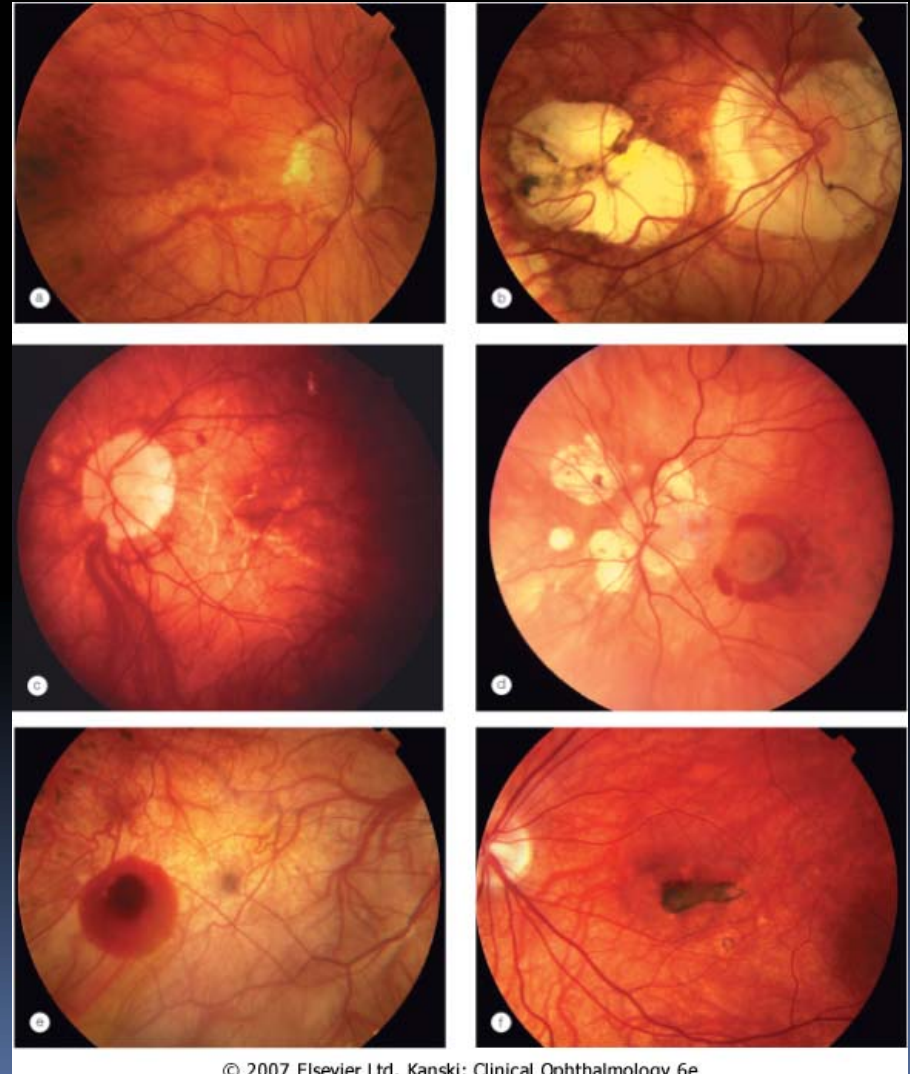
Other Treatment Modalities

- Steroids
 - Cataracts, secondary OAG, sterile endophthalmitis
- Radiation therapy
- Sub-macular surgery
 - Results disappointing
 - Sub-macular Surgical Trials (SST)
 - AMD, POHS and idiopathic CNV
 - POHS membranes better prognosis
- Macular Translocation surgery

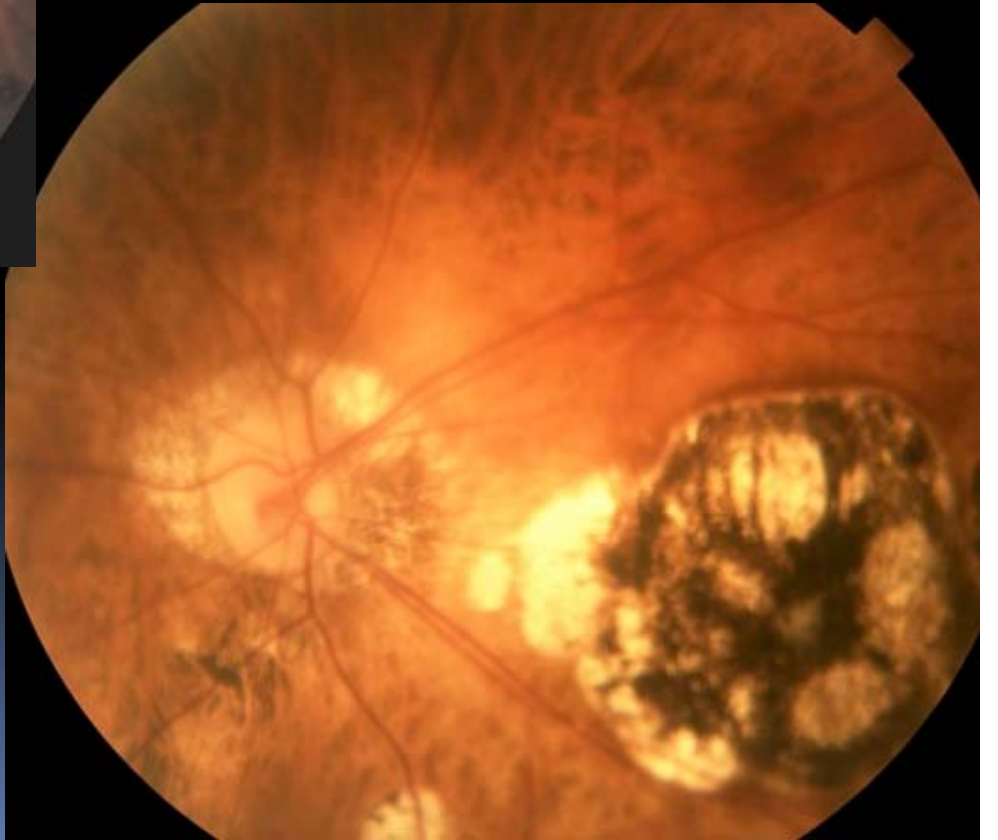
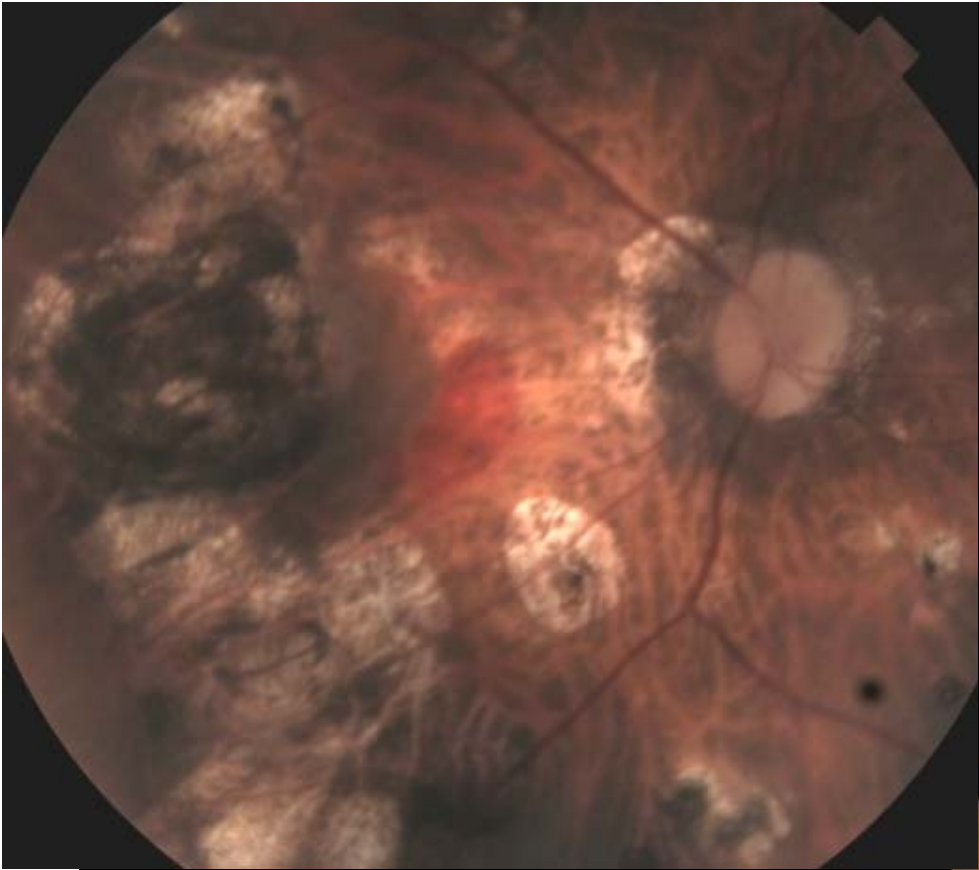


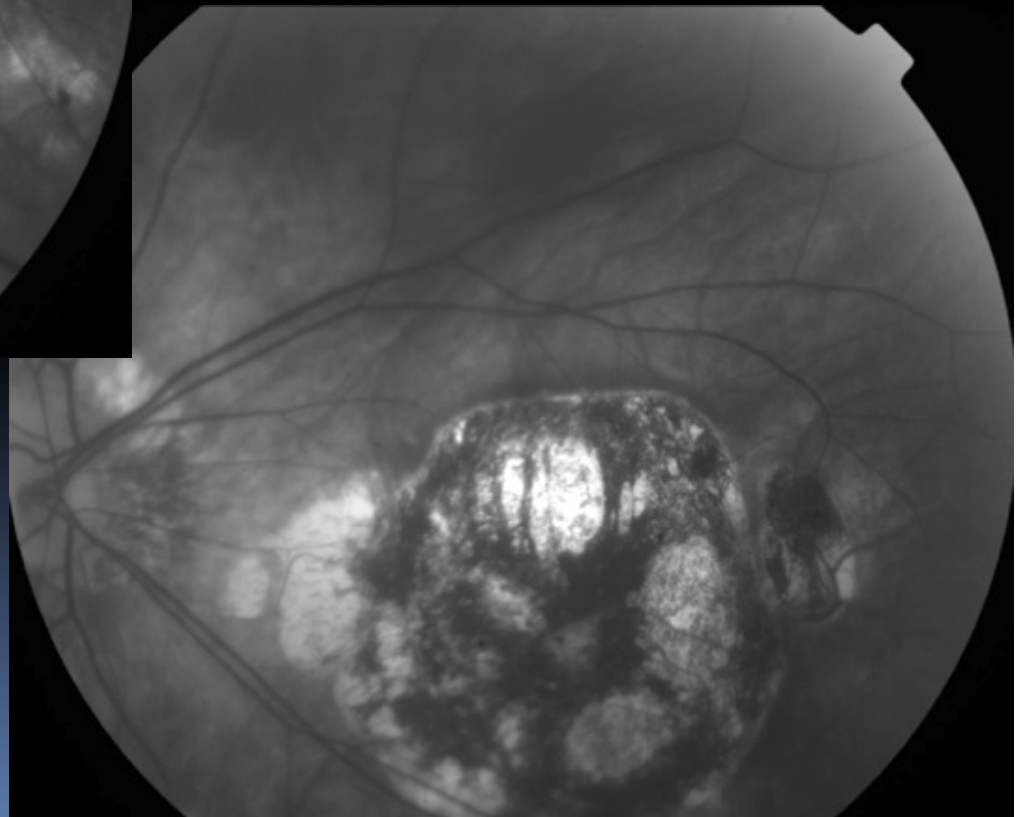
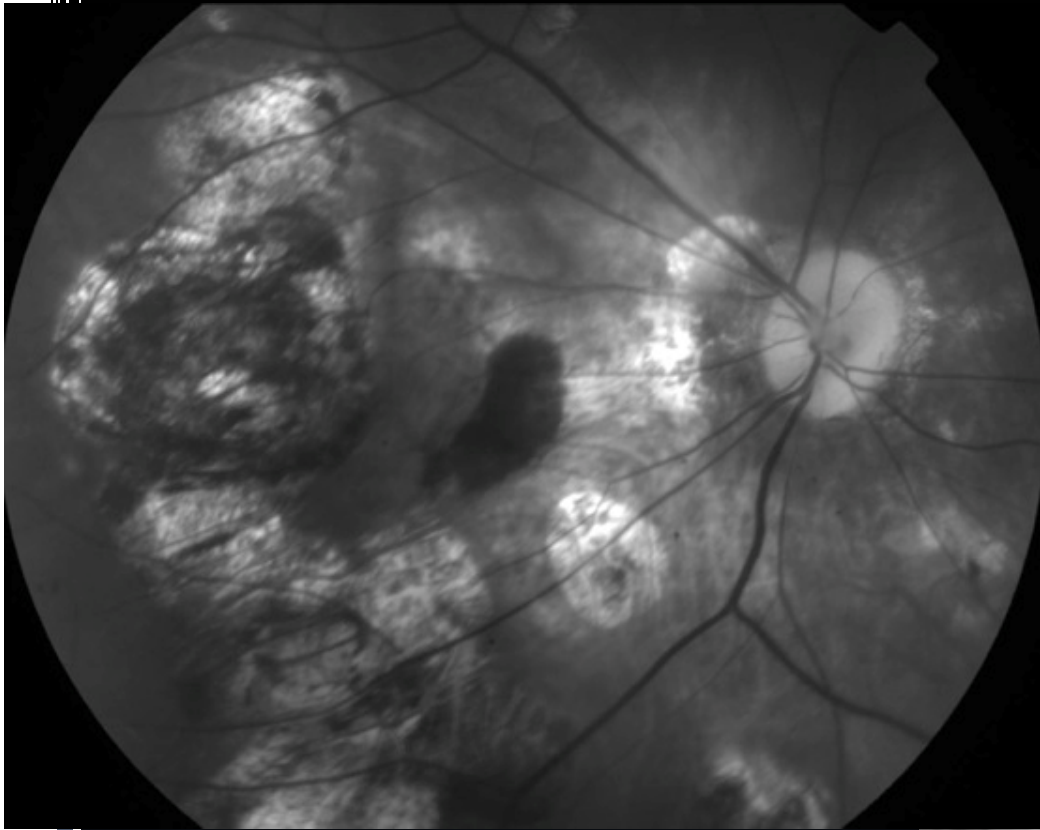
Myopic Degeneration

- -6.00 D or more
- Axial length 26.5 mm or longer
- Tilting of the optic disc, PPA
- Lacquer cracks
- Subretinal hemorrhages, CNV
- Fuchs spots
- Posterior staphyloma
- Gyrate areas of chorioretinal atrophy
- Cystoid, cobblestone, lattice degenerations
- Retinal detachment, holes/tears

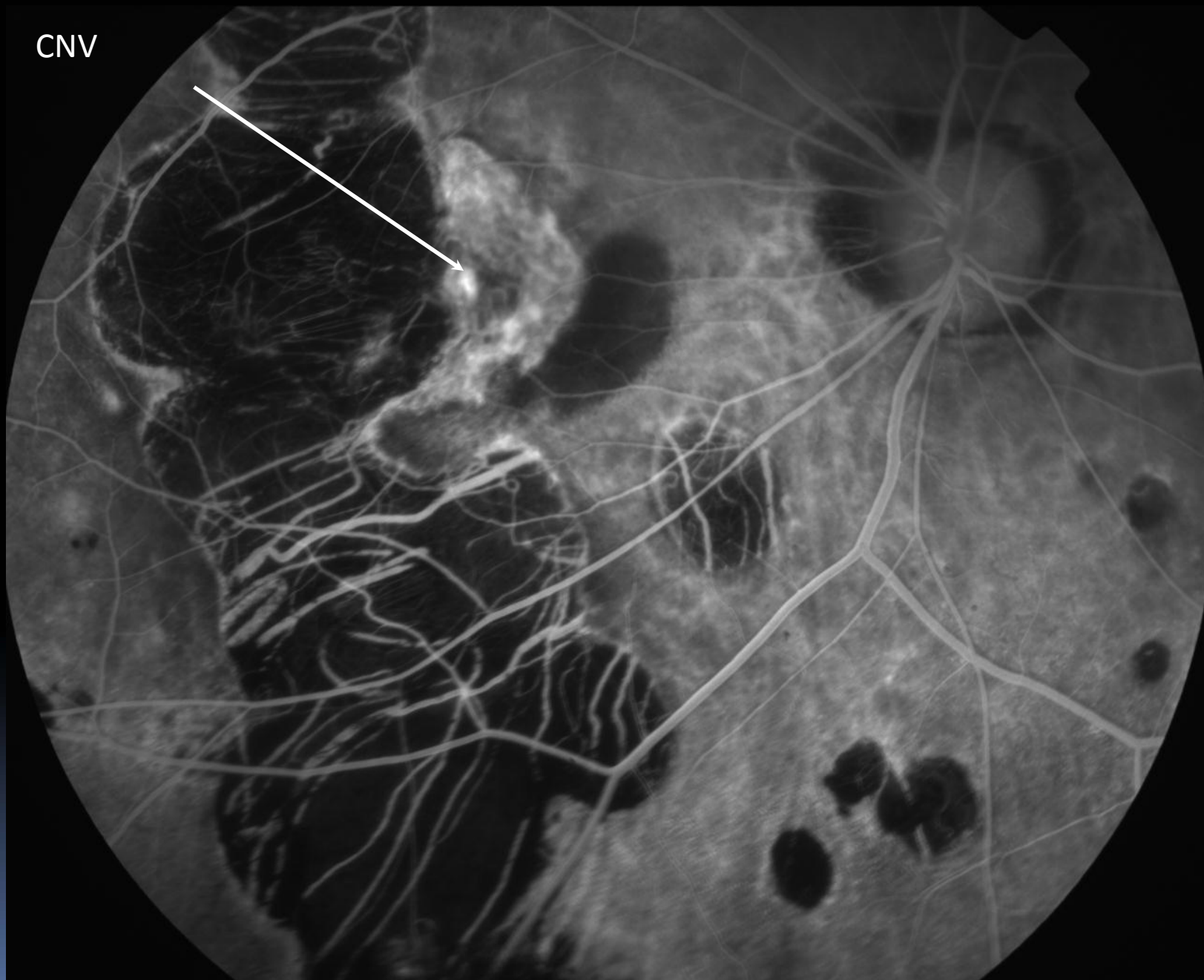


(a) Tessellated fundus; (b) focal chorioretinal atrophy; (c) lacquer cracks; (d) subretinal haemorrhage associated with choroidal neovascularization; (e) 'coin' haemorrhage; (f) Fuchs spot





CNV



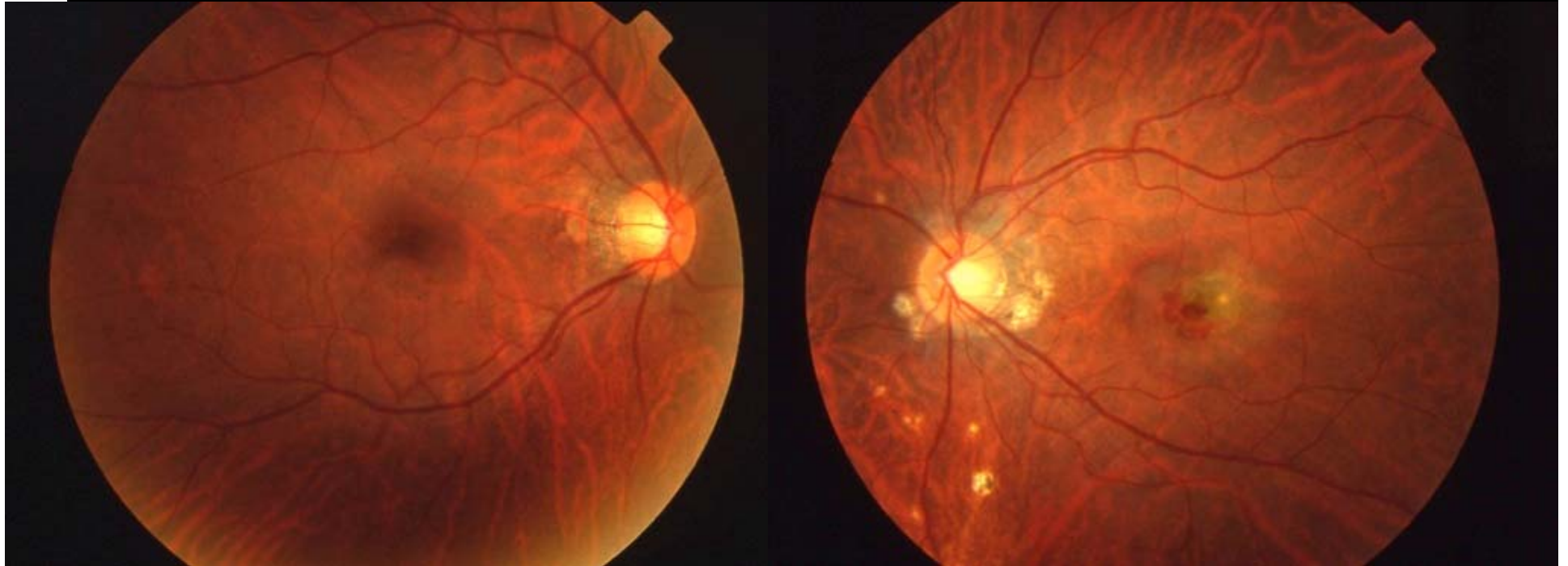
CNV in Myopia

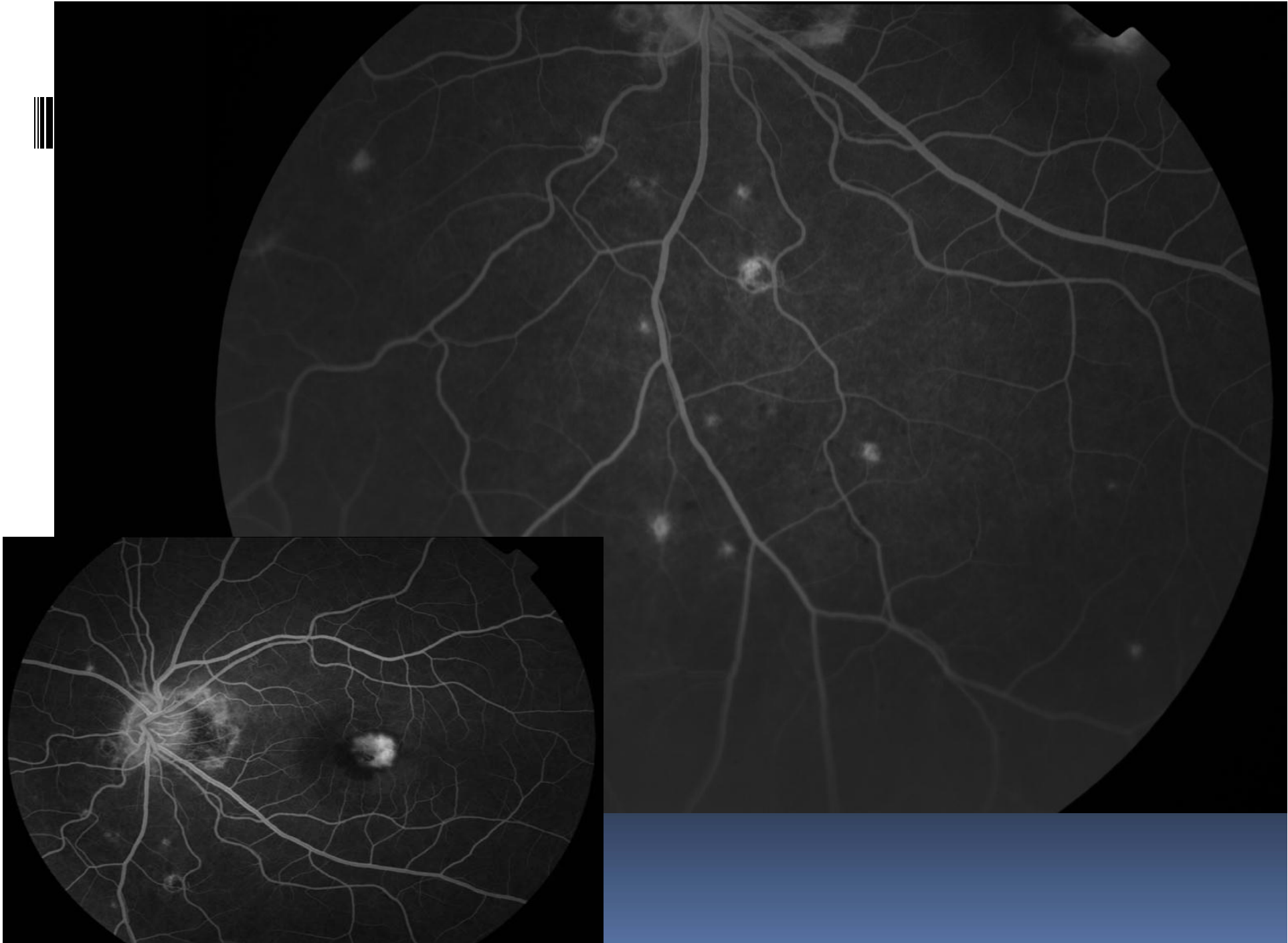
- 5-10% of eyes longer than 26.5mm develop CNV
- Treatment Options
 - Anti-VEGF
 - Photocoagulation in extra-foveal or juxta-foveal lesions (more likely to develop expanding RPE lesions in areas of laser scars)
 - PDT for sub-foveal lesions



What other conditions can give
CNV?

Case



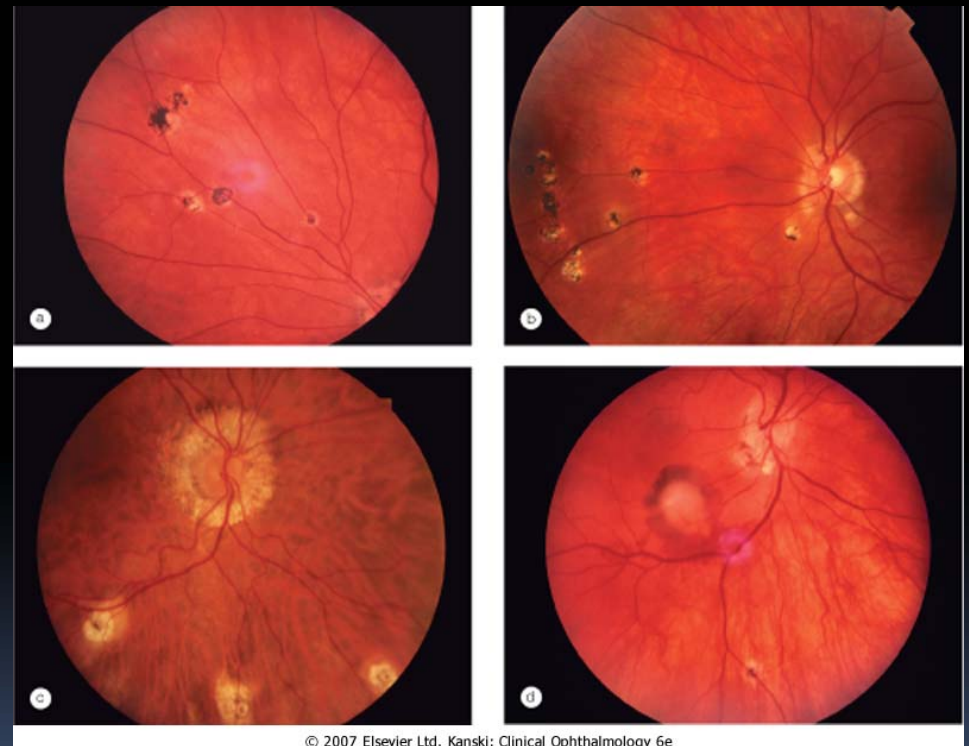

Presumed Ocular Histoplasmosis Syndrome (POHS)

- Infection with *Histoplasma capsulatum* endemic in Mississippi and Ohio river valleys
- Relationship between fungal infection and eye disease supported by epidemiologic and histopathologic data
- Represents immune-mediated response in individuals previously exposed to the fungus

Presumed Ocular Histoplasmosis Syndrome (POHS)

- Clinical appearance:
 - Small, atrophic, punched-out chorioretinal scars (histo spots)
 - NO vitritis (if vitritis – MCP)
 - Linear peripheral atrophic tracks
 - Classic triad: CNV, PPA, histo spots
- Symptomatic when maculopathy



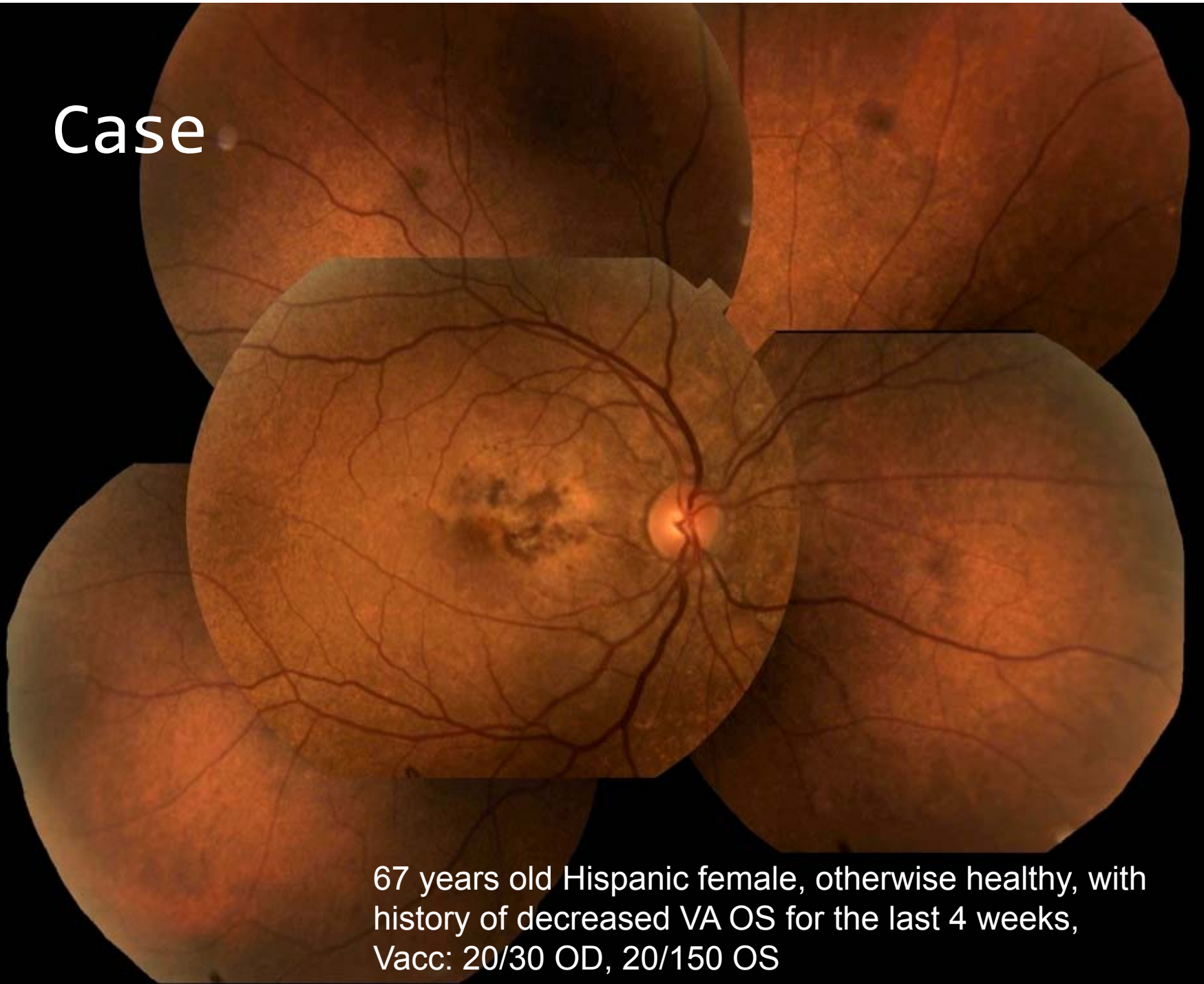POHS Treatment

- Anti-VEGF for CNV
- Verteporfin (PDT) in Ocular Histoplasmosis study (VOH)
 - Beneficial for sub-foveal CNV
 - FDA approved
- MPS
 - Extrafoveal CNV (treated 9% \geq 6 line loss vs. 44% untreated)
 - Juxtafoveal CNV (treated 12% \geq 6 line loss vs. 28% untreated)
 - Subfoveal and Recurrent: no Tx benefit
- Sub-macular surgery
 - For sub-foveal type 2 (anterior to RPE)
 - Sub-optimal results

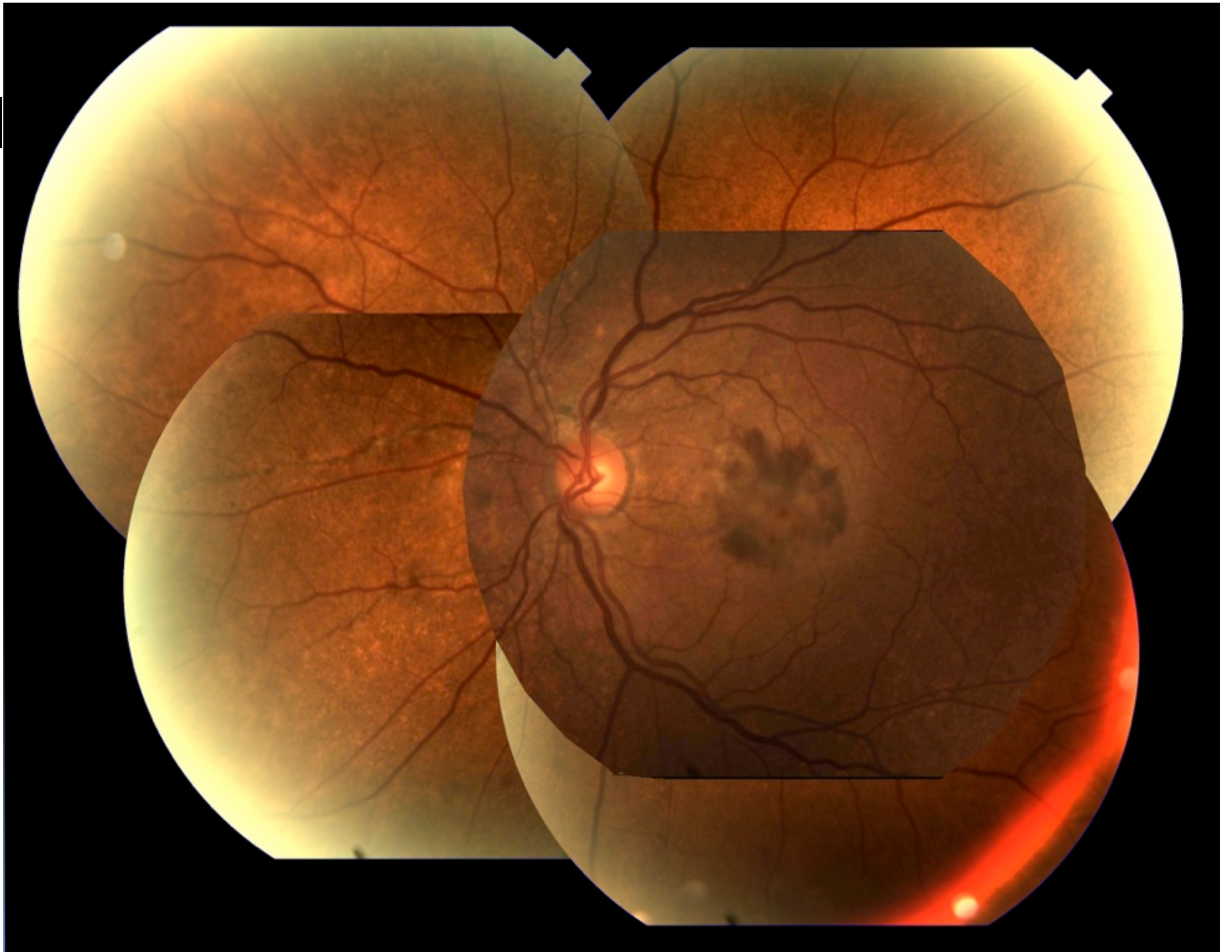


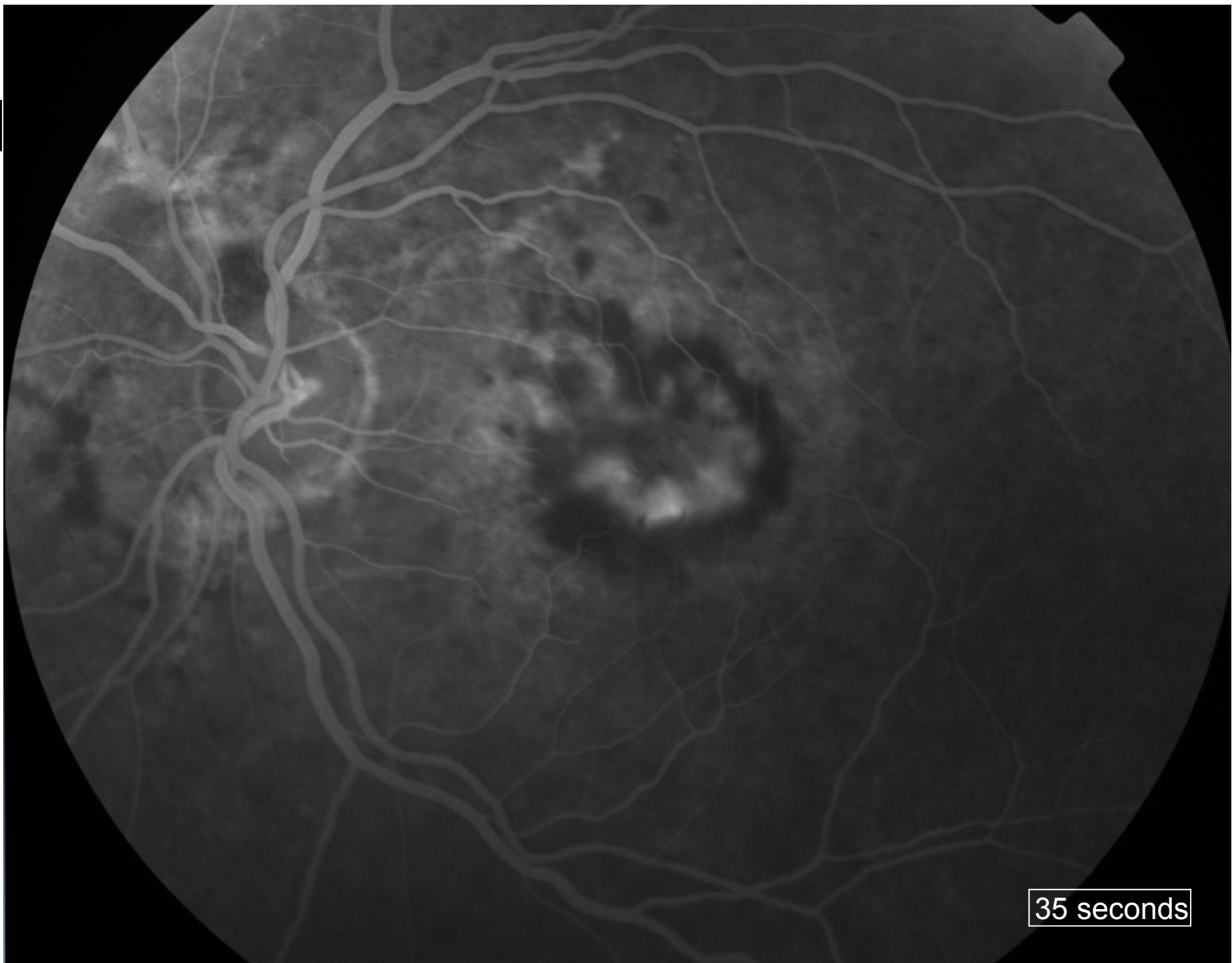
What other conditions can give
CNV?

Case



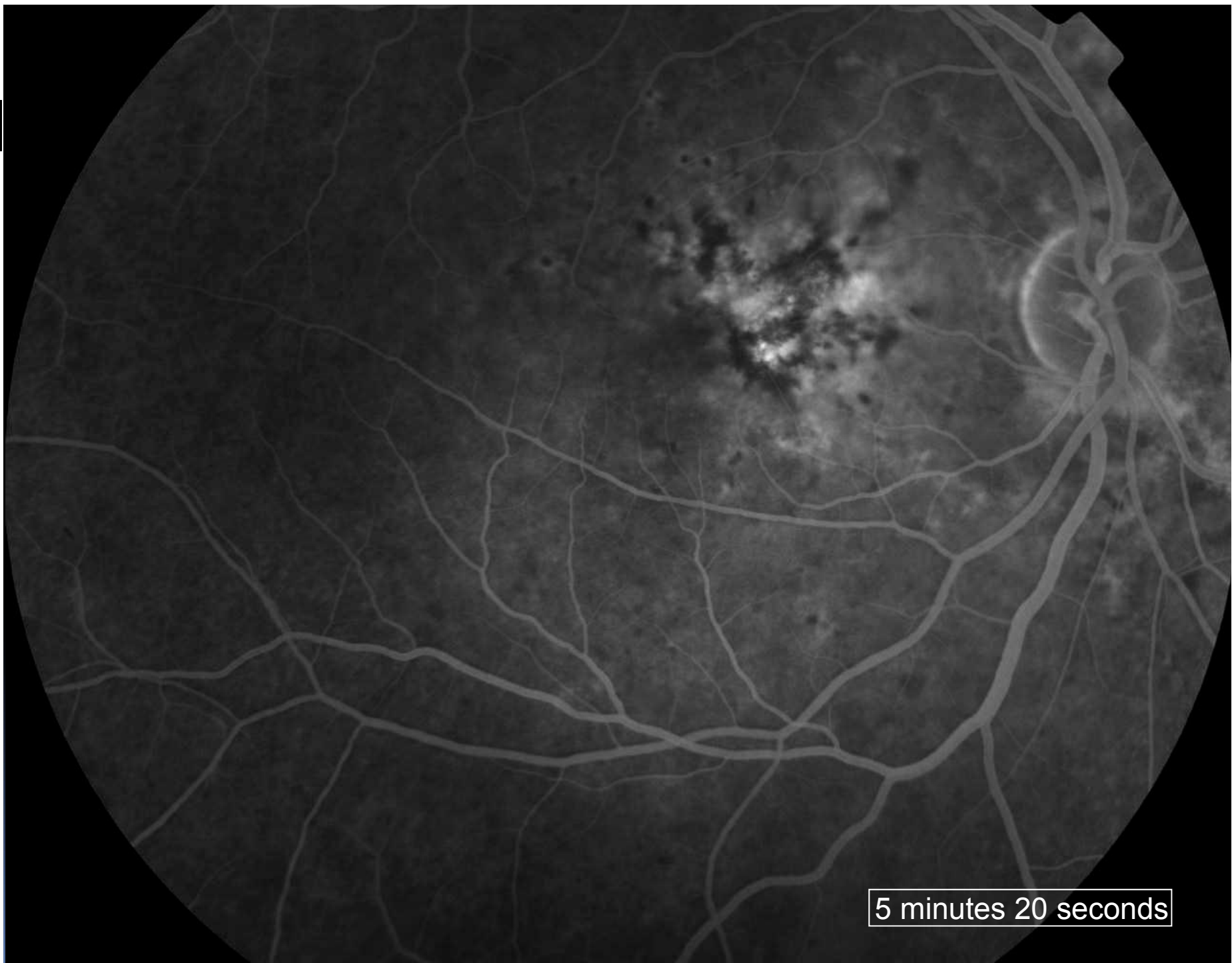
67 years old Hispanic female, otherwise healthy, with history of decreased VA OS for the last 4 weeks, Vacc: 20/30 OD, 20/150 OS

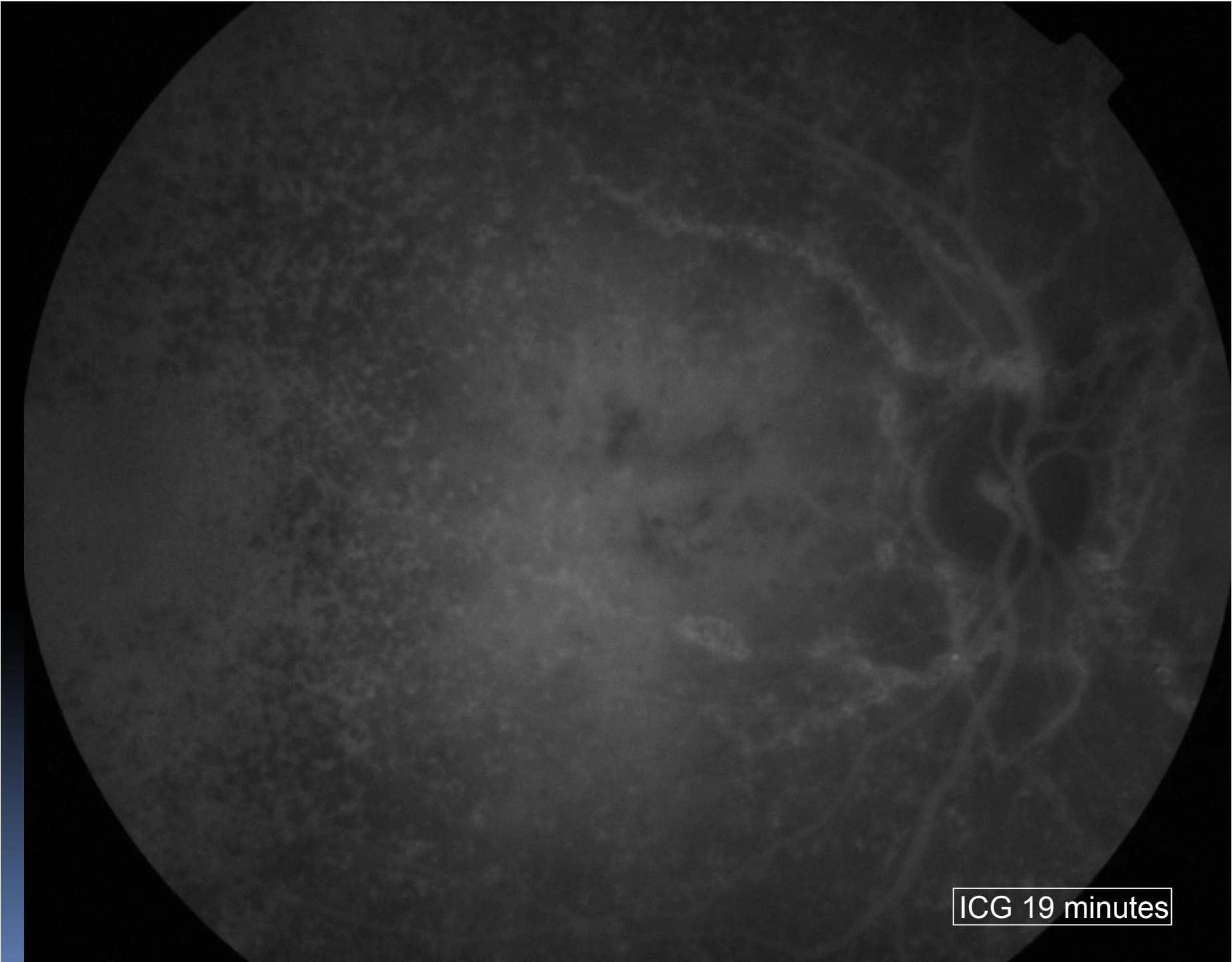




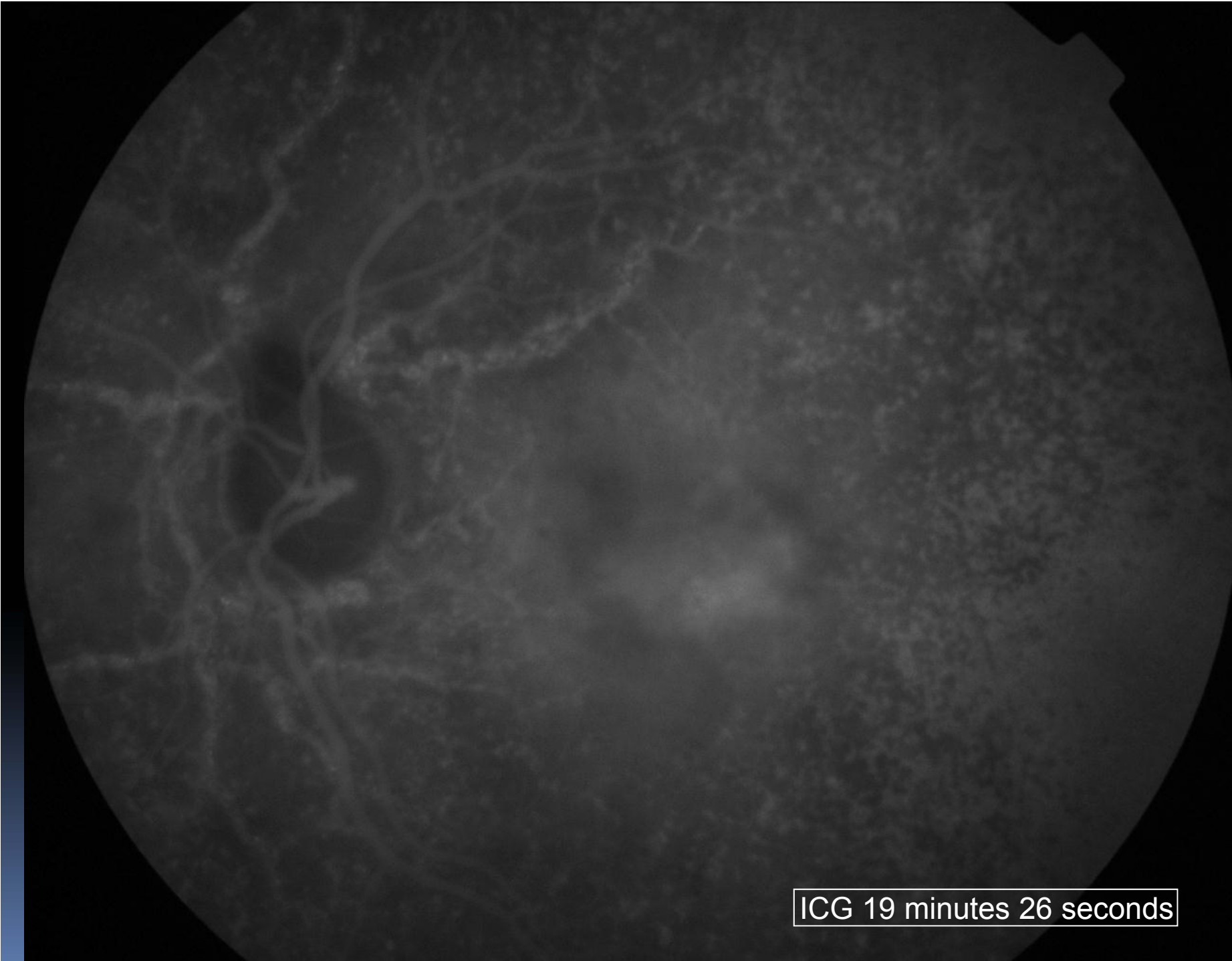
35 seconds

5 minutes 20 seconds

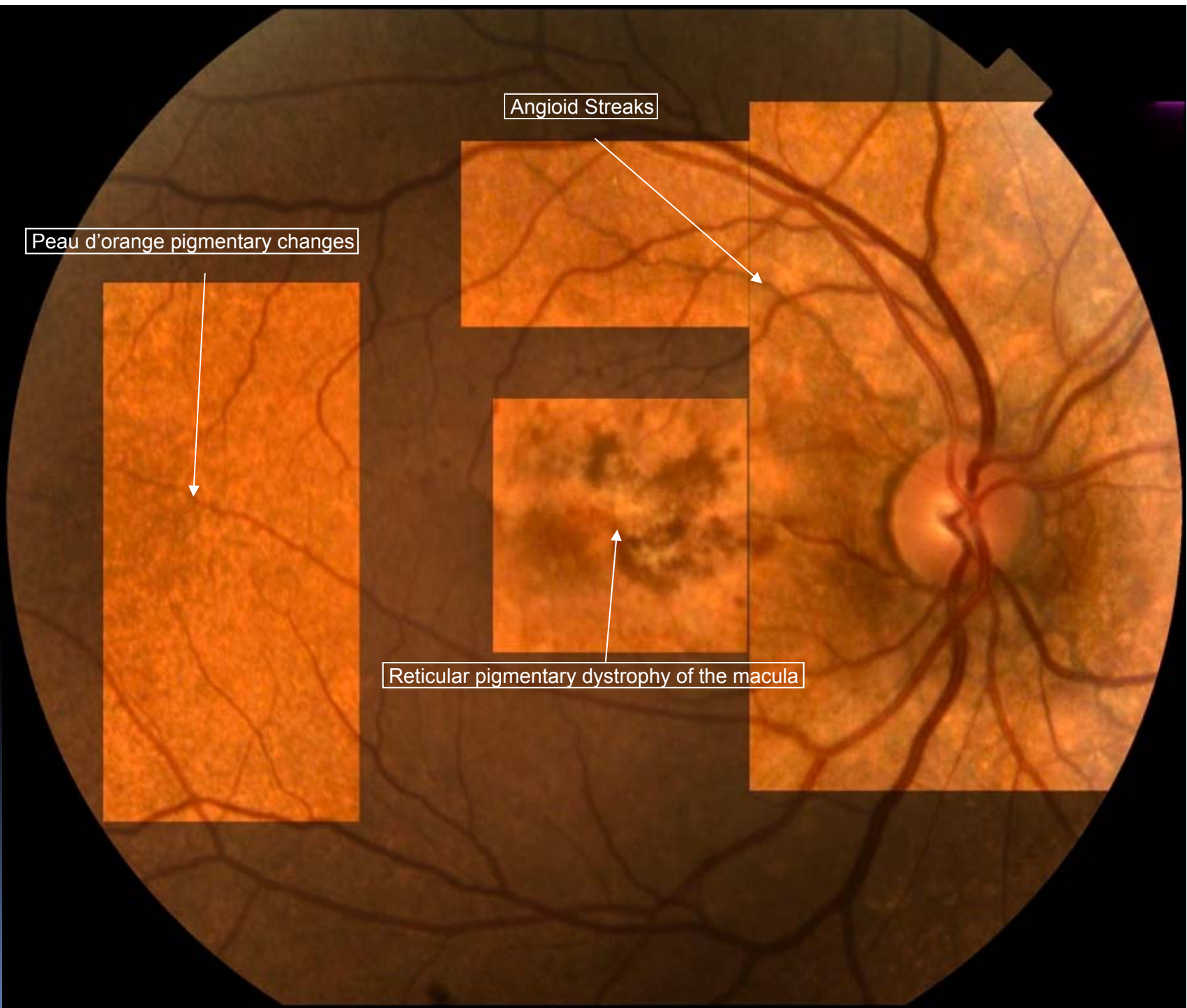




ICG 19 minutes



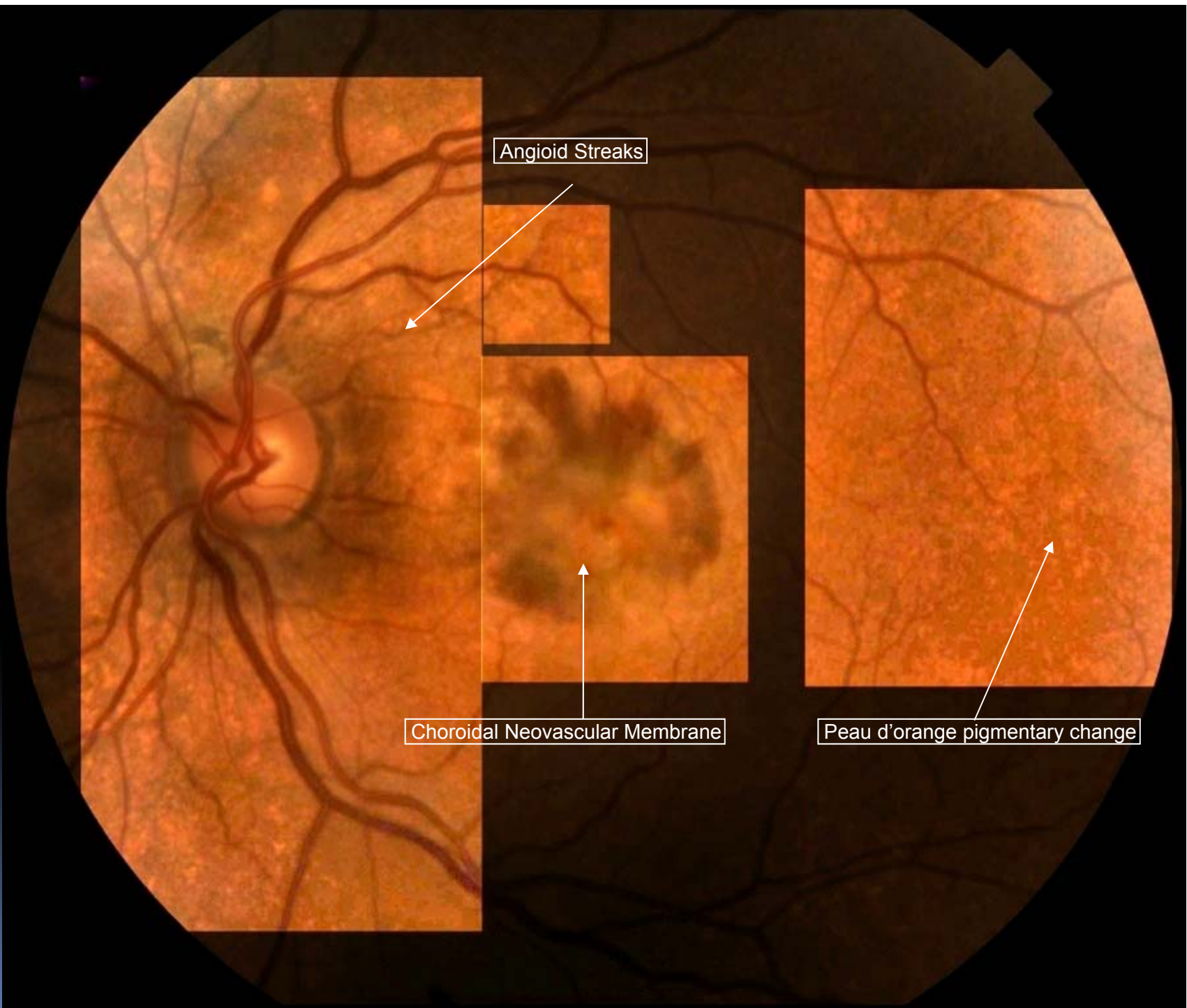ICG 19 minutes 26 seconds



Angioid Streaks

Peau d'orange pigmentary changes

Reticular pigmentary dystrophy of the macula



Angioid Streaks



Choroidal Neovascular Membrane

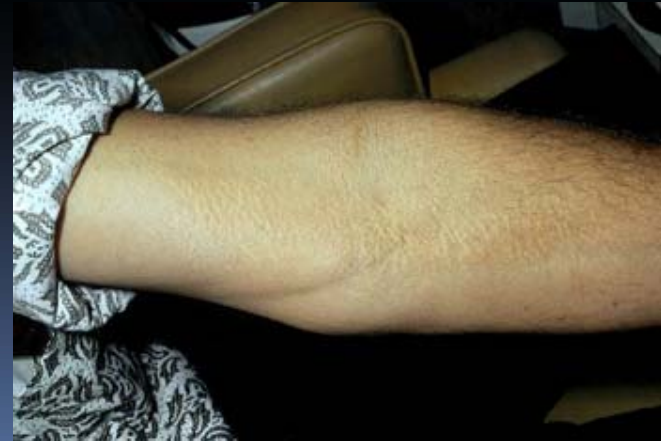
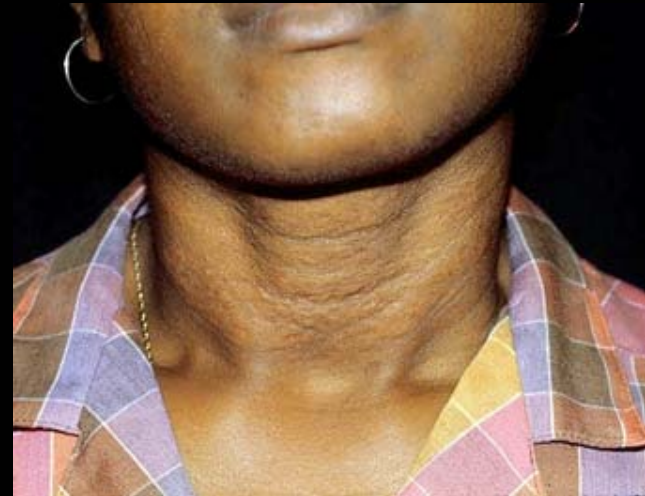
Peau d'orange pigmentary change



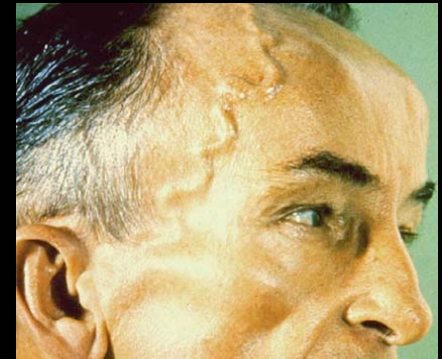
Angioid Streaks

- Pseudoxanthoma elasticum (PXE)
 - Plucked chicken appearance to skin
 - Degeneration and calcification of the elastic tissue of the dermis
 - Calcification of the large arteries of the extremities and with gastrointestinal bleeding



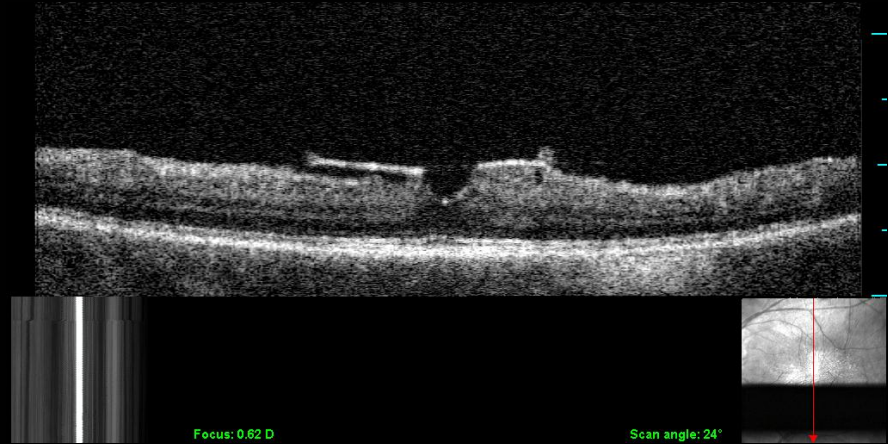
Angioid Streaks

- Remember PEPSI
 - Pseudoxanthoma elasticum (AR)
 - Ehler-Danlos (AD)
 - Paget's disease (AD)
 - Enlargement of the skull, deformity of the long bones, kyphoscoliosis, and hearing loss
 - Sickle cell disease (usually AD)
 - Idiopathic (50%)



Epiretinal Membranes

- Etiology:
 - Idiopathic
 - Secondary
 - Trauma
 - Uveitis
 - Retinal breaks
 - Vasculopathy (DM, RVO)
 - Intraocular surgery

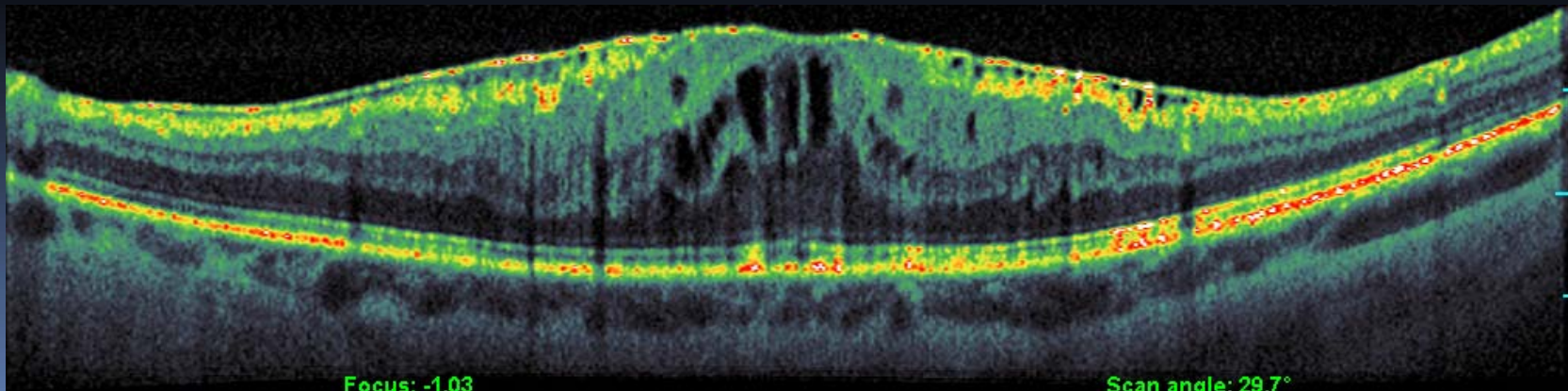


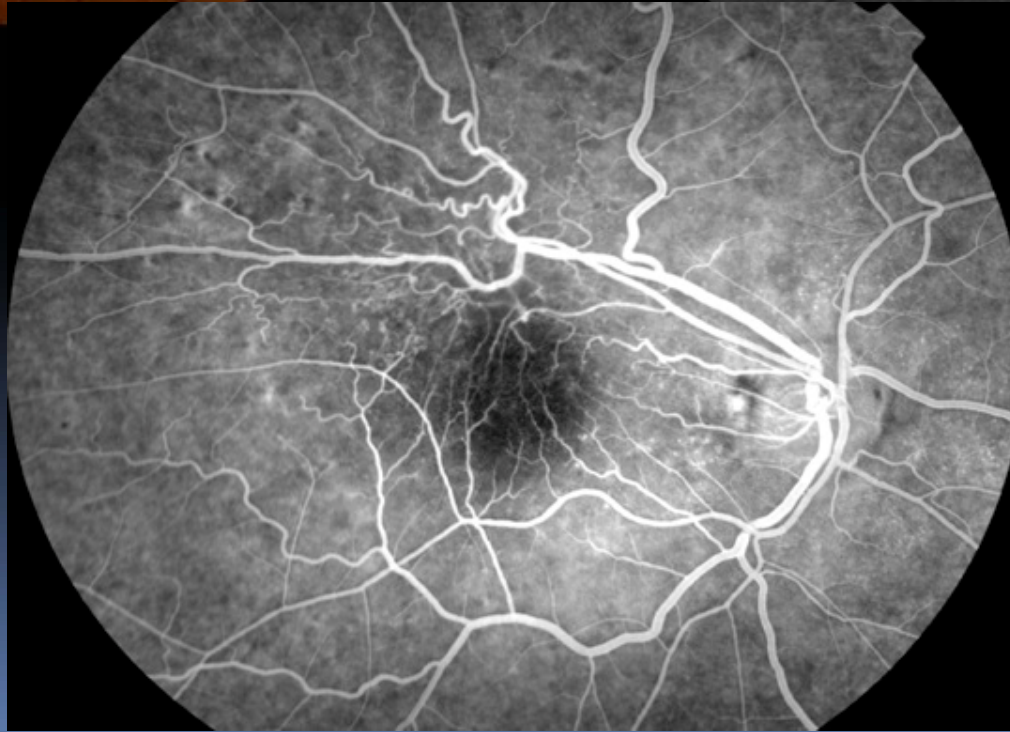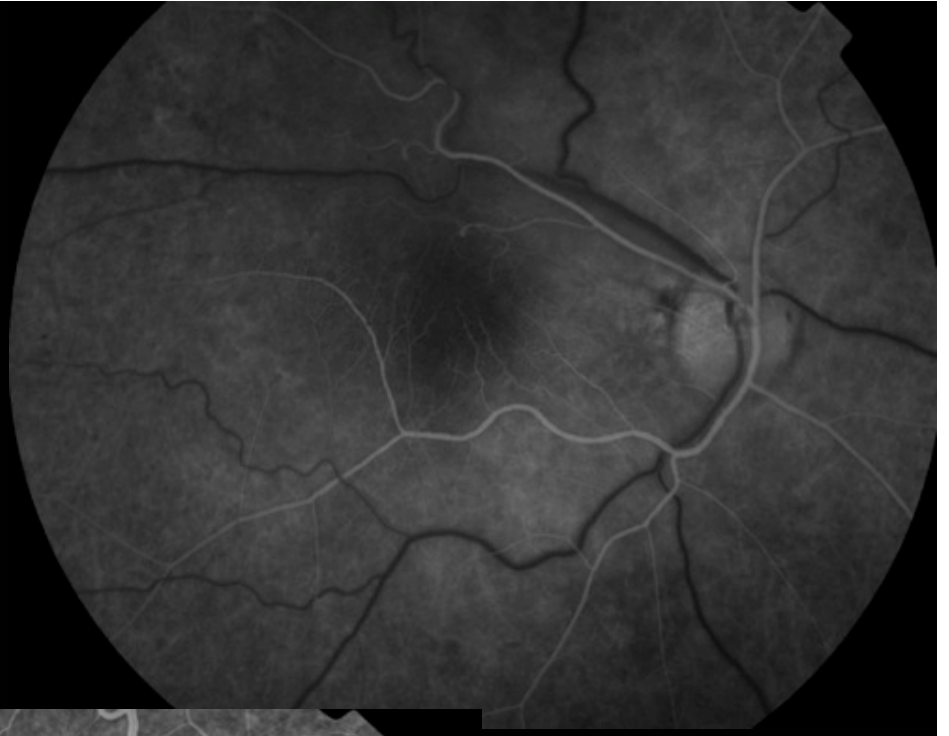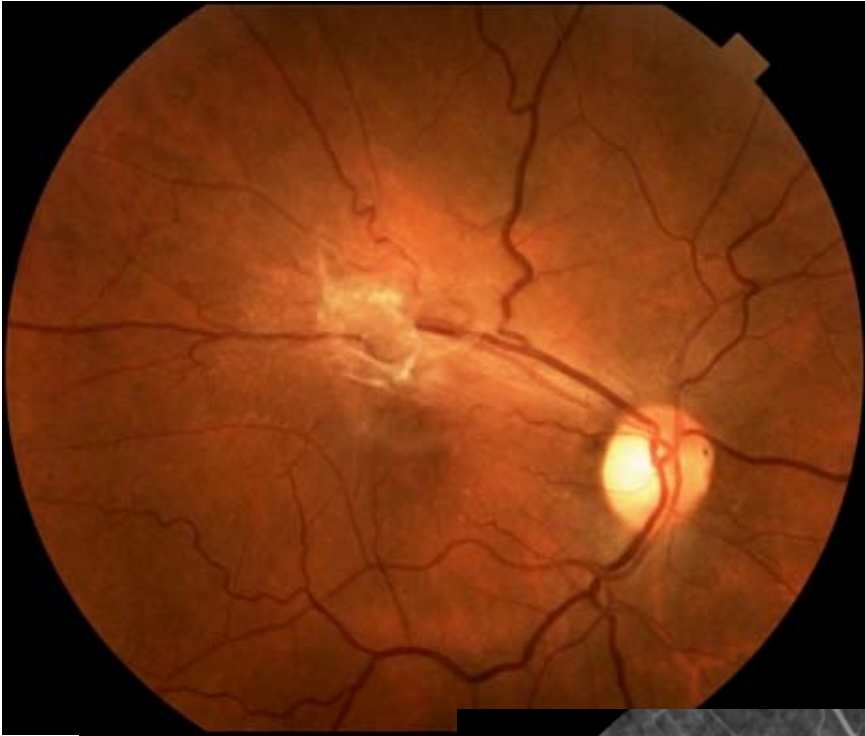Epiretinal Membranes

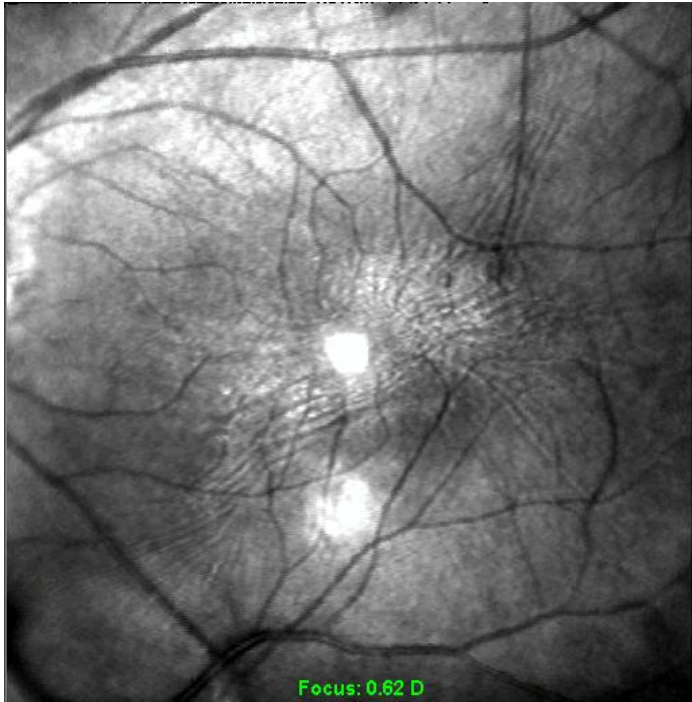- Population:
 - Patients > 50 years of age
 - male = female
- Incidence of bilaterality: ~ 20%
- Characteristics:
 - separation of posterior vitreous
 - tangential traction vectors
 - vascular dragging/changes

Epiretinal Membranes

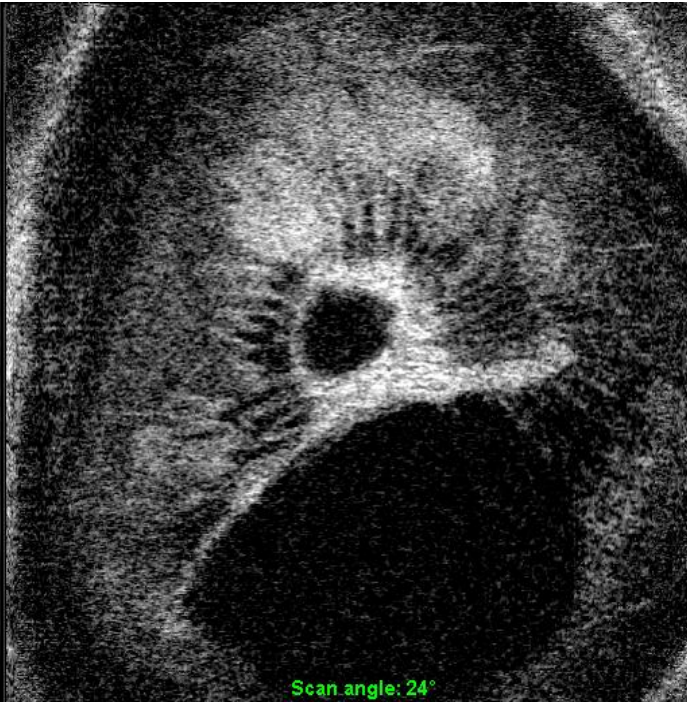- Treatment
 - Medical
 - NSAID's, topical steroids if CME is present
 - Microplasmin (if impending hole)
 - Vitrectomy, membrane peeling if Va less than 20/60 and symptomatic








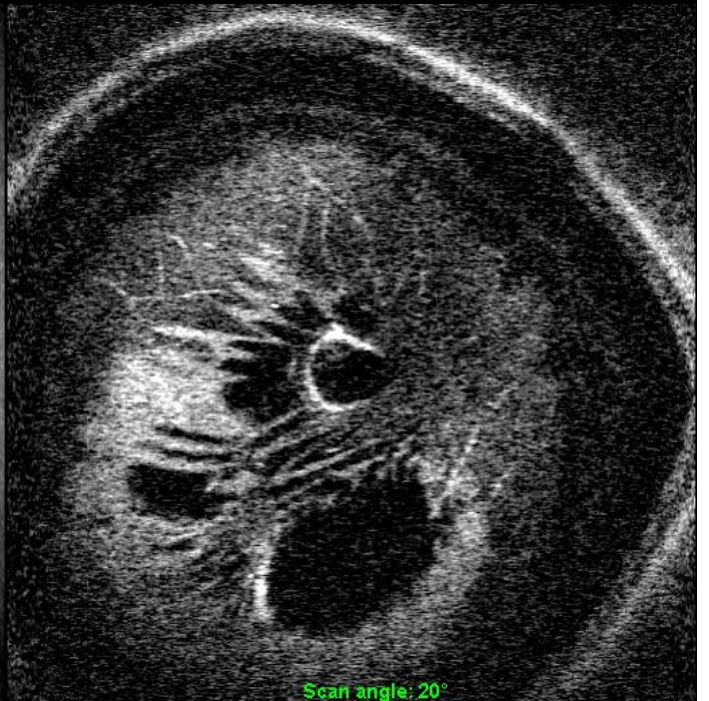
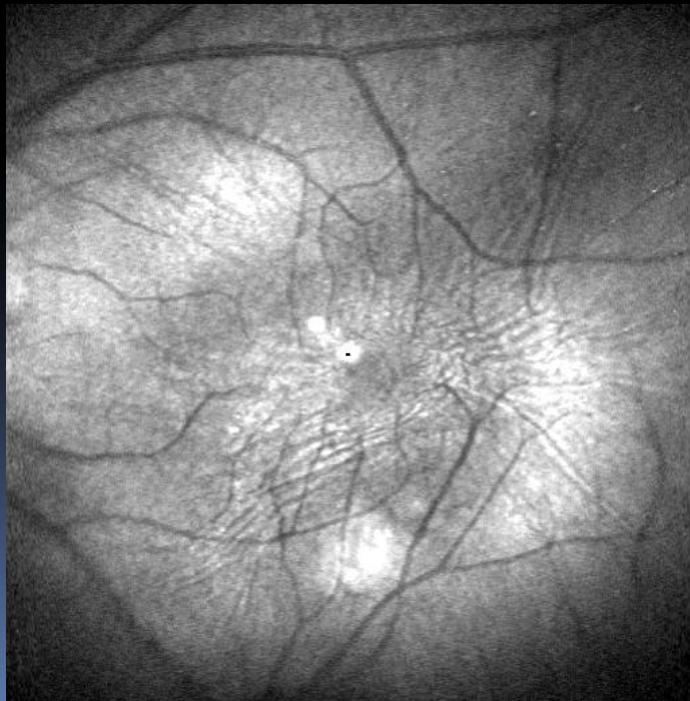
Focus: 0.62 D



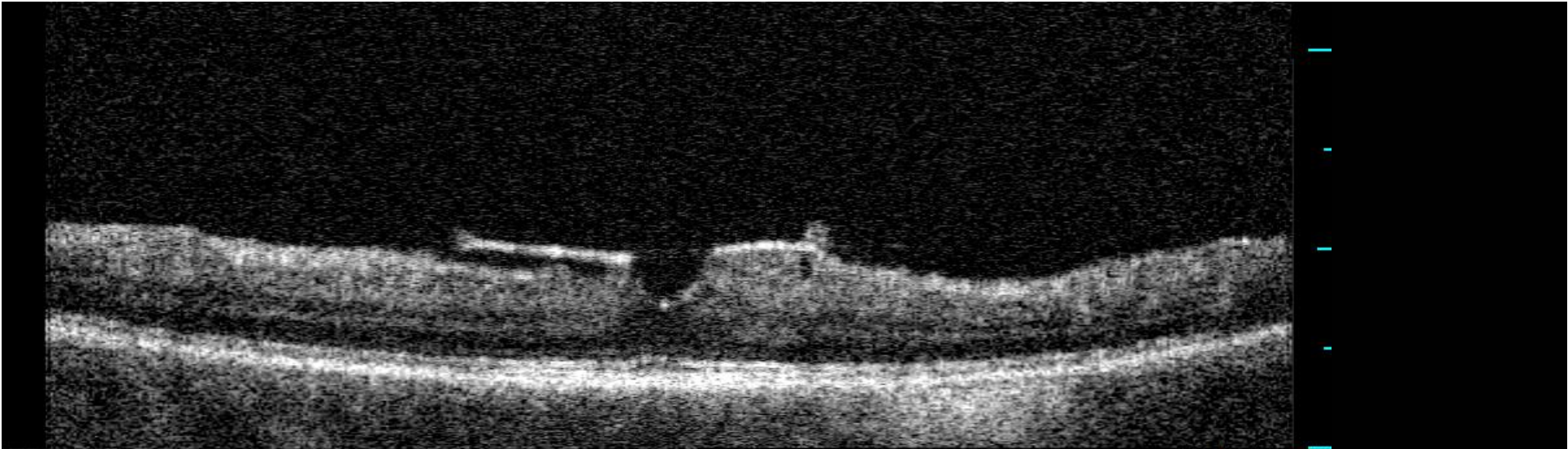
Scan angle: 24°



SLO-OCT
with C-Scan

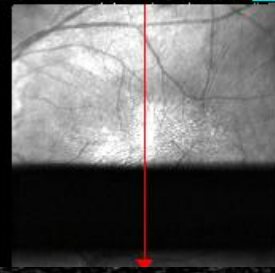


Scan angle: 20°


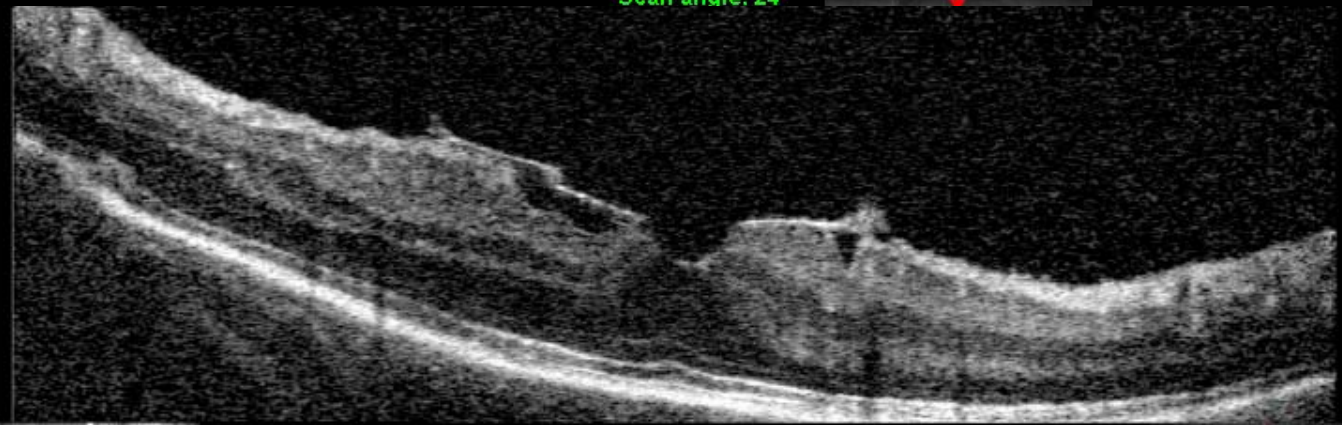


Focus: 0.62 D

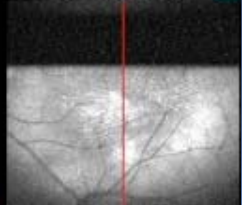
Scan angle: 24°



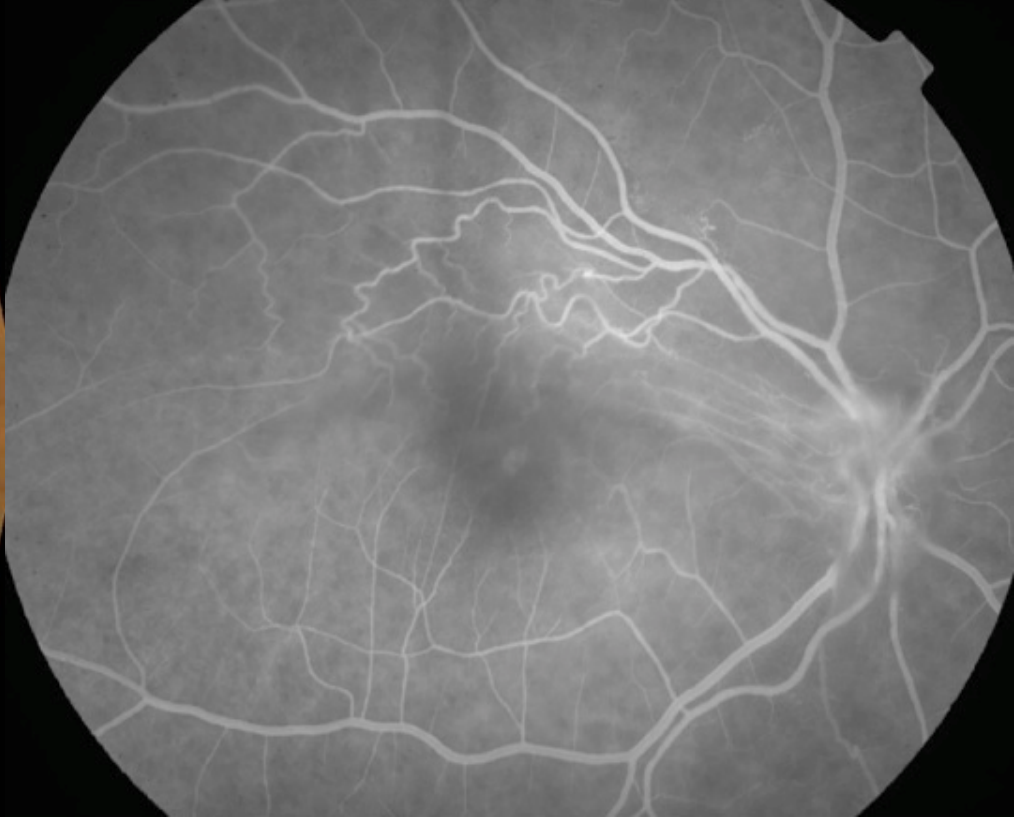
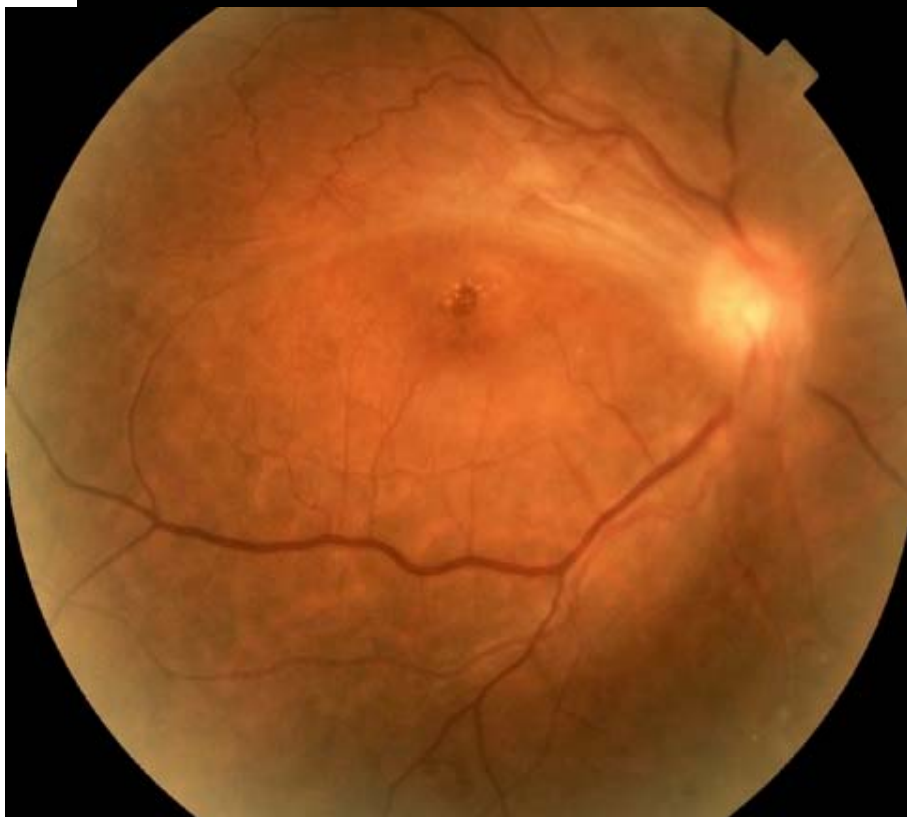
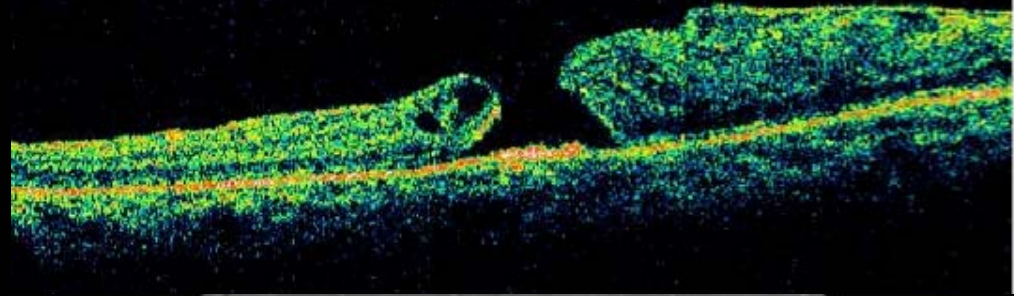
SLO-OCT



Scan angle: 20°



Epiretinal membrane with
stretch macular hole

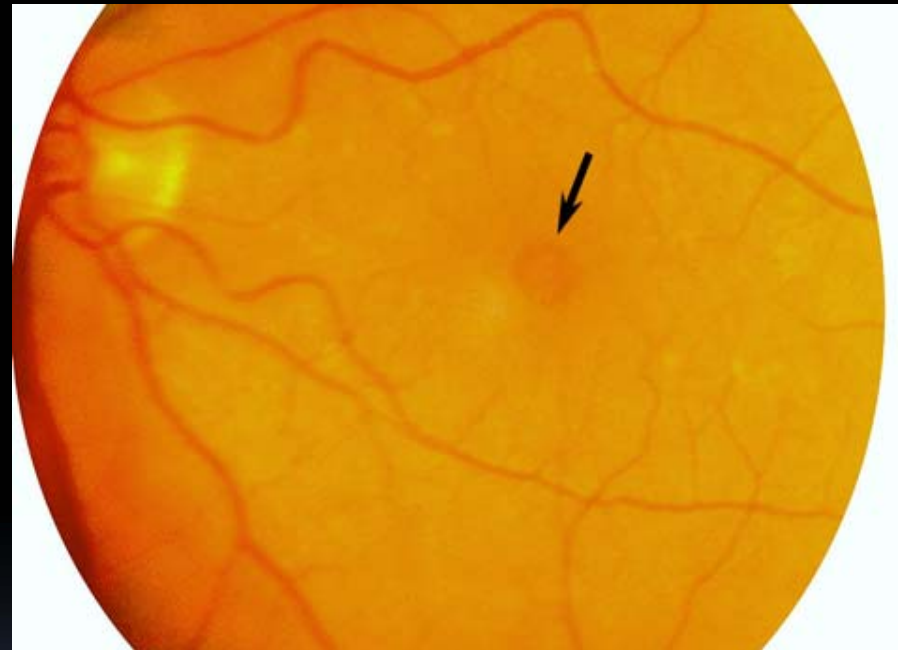

Idiopathic Macular Holes

- Epidemiology
 - 6th – 8th decade of life
 - Women 2-3 time more frequently than men
 - Bilateral in 25-30%
- Pathogenesis
 - Associated with tangential vitreomacular traction
- Other causes
 - High myopia associated with posterior staphyloma, blunt trauma, solar retinopathy

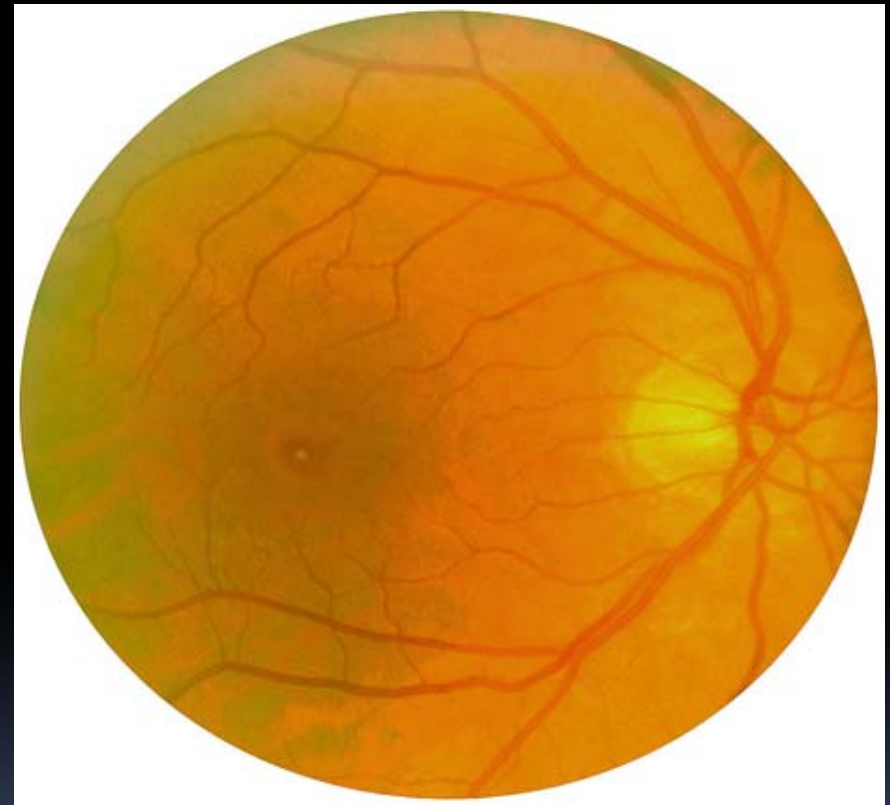Gass – Stage 1– Impending Hole

- ▶ Foveal detachment
 - Focal contraction of the cortical vitreous causing mild loss of VA and metamorphopsia
 - Yellow spot (1A) or ring (1B) with loss of foveal depression
 - 50% spontaneously resolve




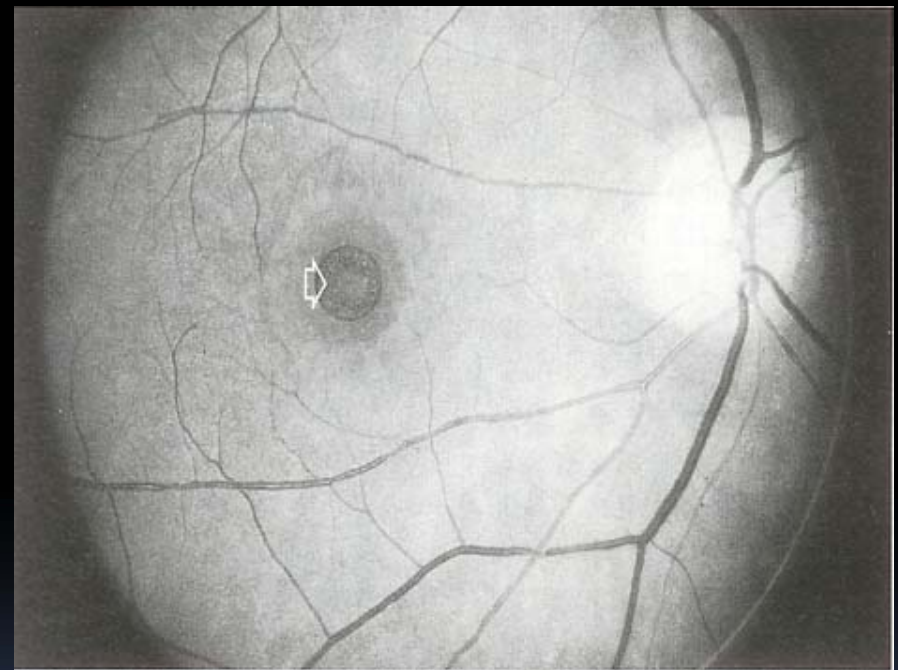
Gass Stage 2

- Stage 2
 - Central round or peripheral crescent or a horseshoe-shaped full-thickness macular hole (<400 microns)
 - VA worse
 - Progression from stage 1 to 2 takes between a week to several months



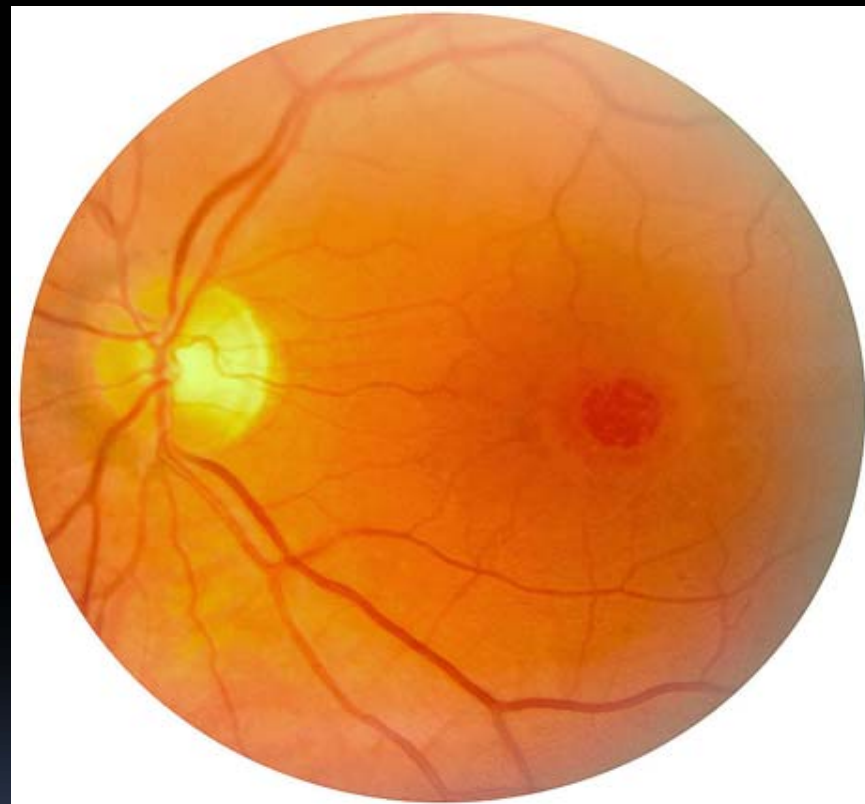
Gass Stage 3

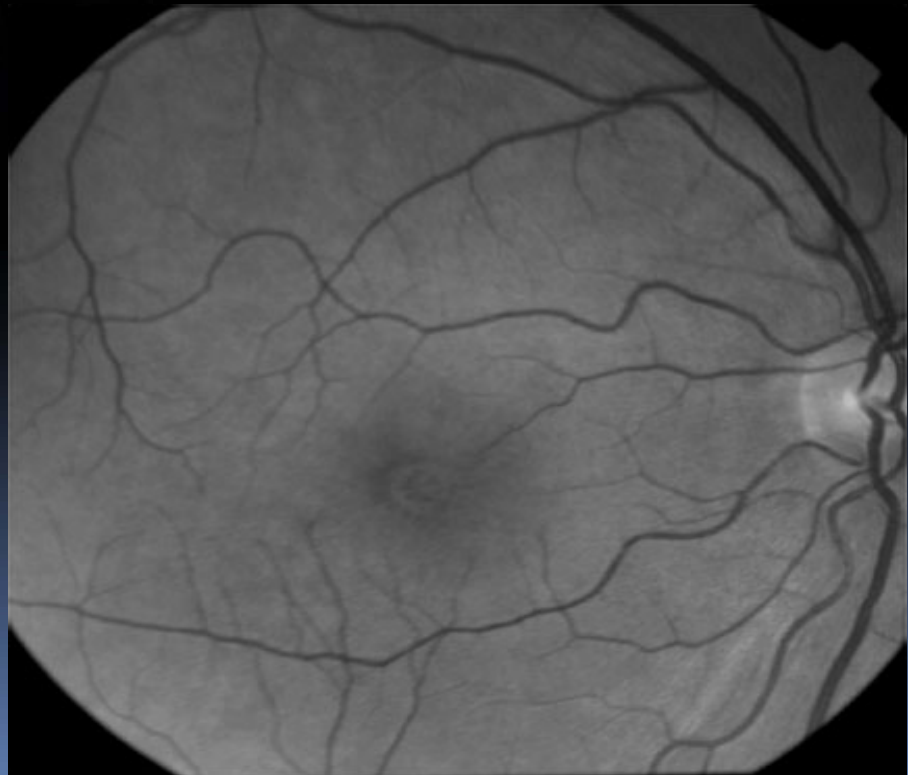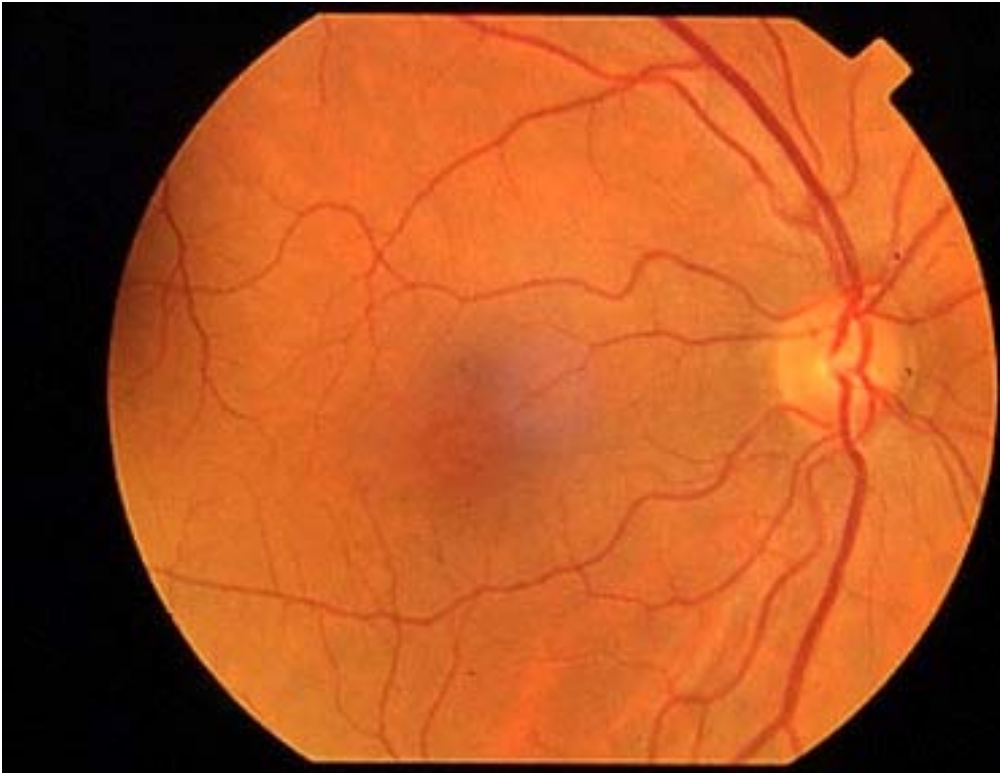- Larger hole (>400 microns) and typically with rim of elevated retina
- VA 20/40 – 5/200, usually around 20/200
- CME common and photoreceptor atrophy within detached retina
- Incomplete separation of cortical vitreous



Gass Stage 4

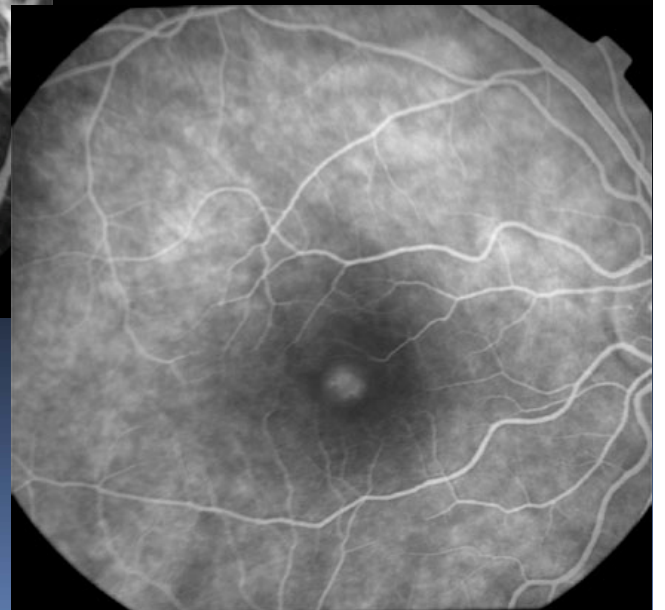
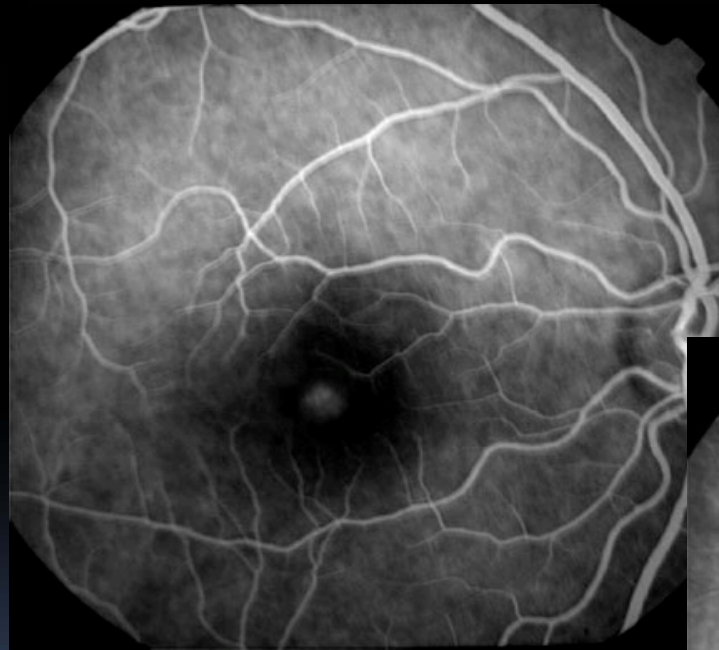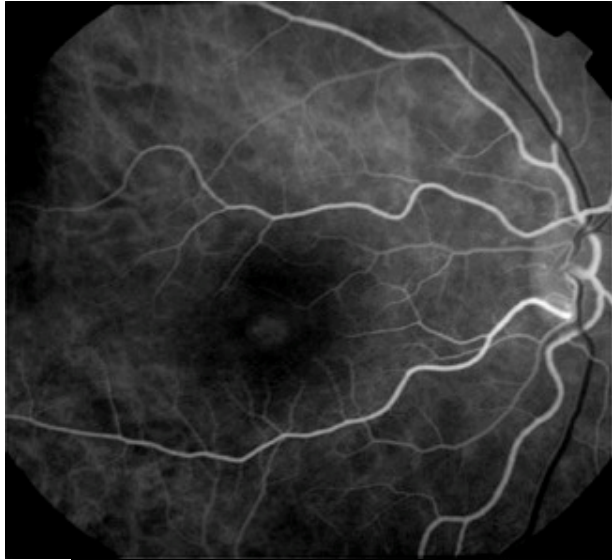- Complete separation of the posterior cortical vitreous
 - Weiss ring
- Large (>400 microns)
- Watzke-Allen test positive





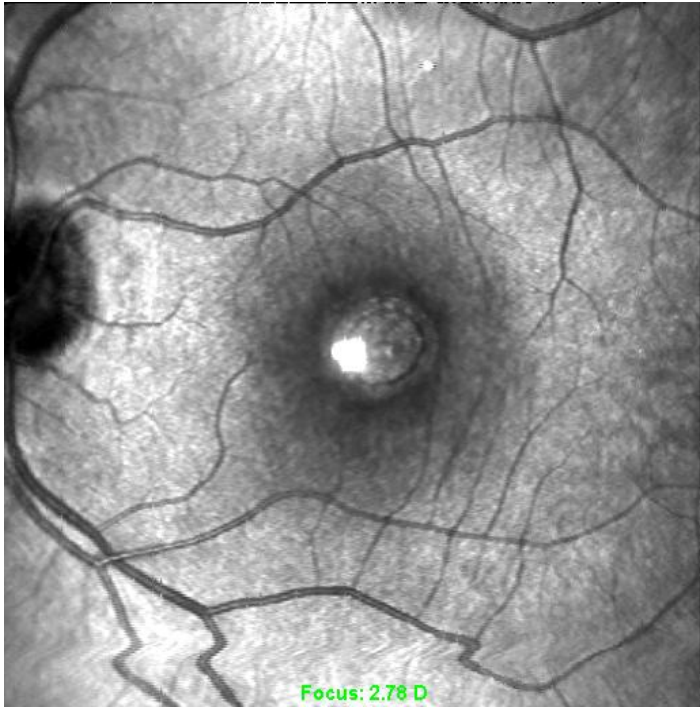Fluorescein Angiogram



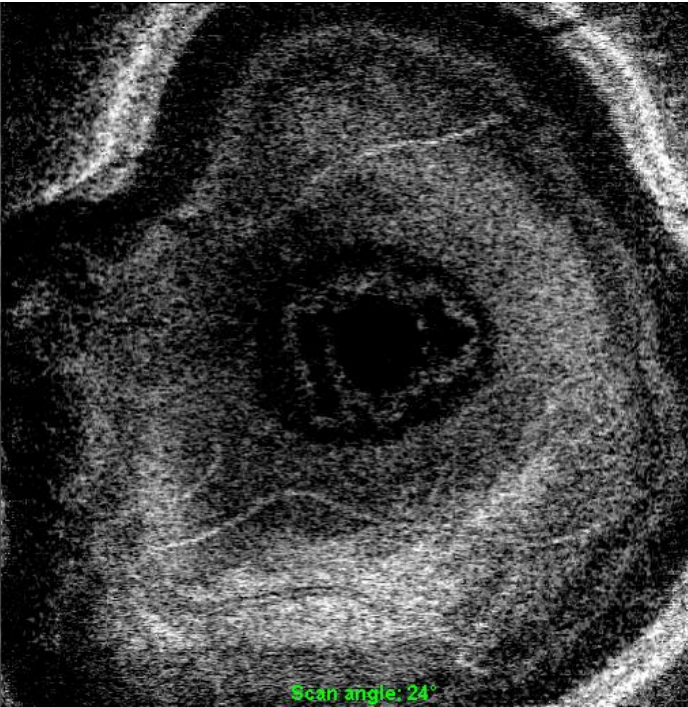


Window
defect





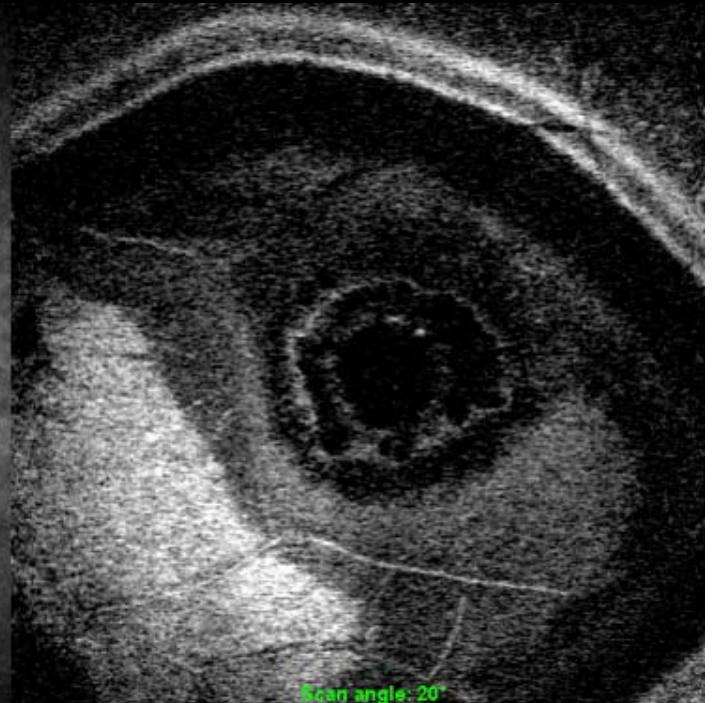
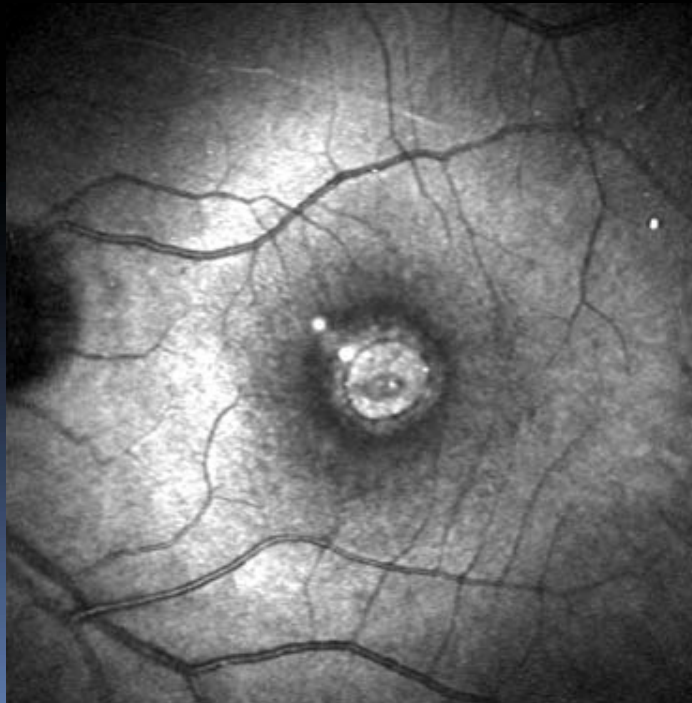
Focus: 2.78 D



Scan angle: 24°



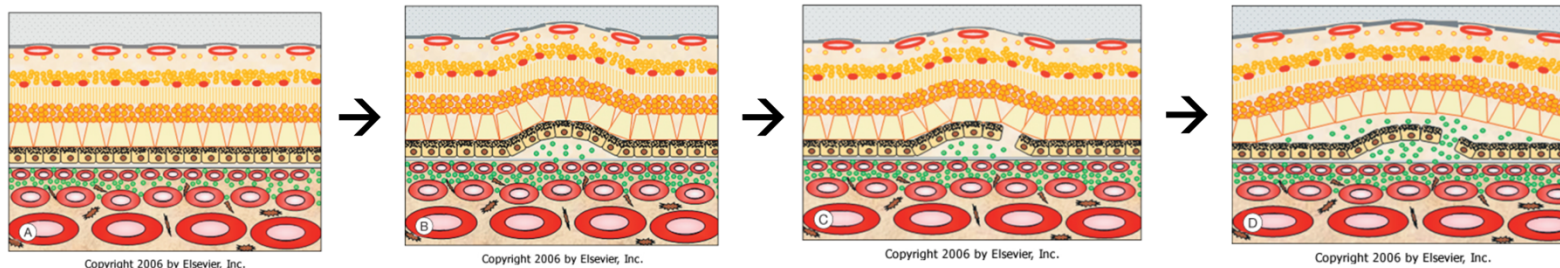
SLO-OCT
image with
C-scan



Scan angle: 20°

Central Serous Chorioretinopathy (CSCR)

- Classic theory, *Ryan SJ. Central serous chorioretinopathy. Retina 4th ed. 2006;*



1. Choroidal hyperpermeability and choriocapillary congestion and exudation of protein & fluid
2. RPE pump decompensates over time, PED forms
3. RPE defect develops and fluid leaks into subretinal space
4. Neurosensory retina elevates in a neurosensory detachment

- The cause of choroidal hyperpermeability not known, but speculated to be secondary to stasis, ischemia, inflammation, or a combination of all these, *Yannuzzi, 2010*

Classic vs. Chronic CSCR

- 2 major types of CSR
 - Classic – recent onset of disease with 1 or only a few focal leaks from RPE
 - Better prognosis
 - Chronic (aka diffuse retinal pigment epitheliopathy) – broad areas of involvement with granular hyperfluorescence and associated with many indistinct areas of leakage
 - More often bilateral
 - Gravitational tracts
 - Worse visual prognosis
 - VA, stereopsis, color vision, central VF function all affected
- CNV a sequellae in both types

CSCR Epidemiology

- Higher prevalence in men (2.6:1)
- Peak prevalence @ 45yo
- 20-40% bilateral
- Racial predisposition – highest in Caucasians, Hispanics & Asians; extremely rare in AA
- Among non-surgical retinopathies, CSR ranks 4th in incidence after AMD, DR, RVO

CSCR Predilections & Associations

• Psychosocial

- Type A personalities, hysteria, hypochondria
- Stress, especially transient life crises

• Hormonal & Pharmacologic

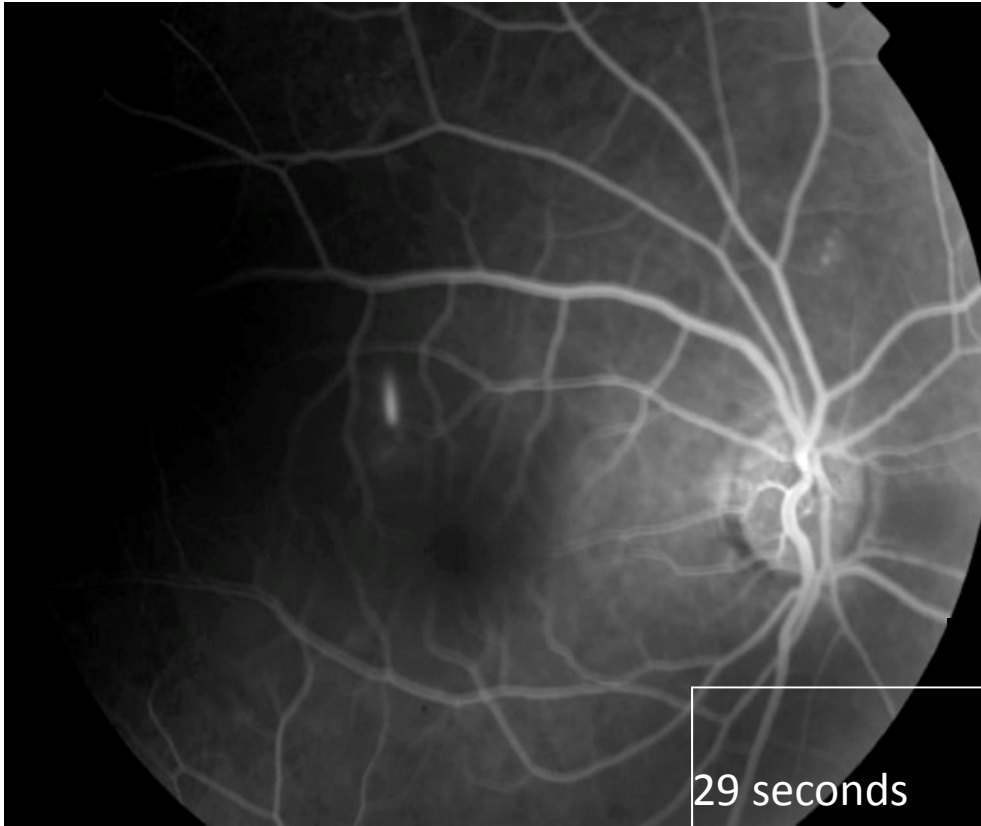
- Glucocorticoids - endogenously & exogenously increased levels
- Catecholamines – increase sensitivity of adrenergic receptors to corticosteroids
 - Epi administration in animals causes serous detachments & RPE apoptosis
- Meds
 - Sympathomimetics (ecstasy, pseudoephedrine, oxymetazoline, decongestants)
 - Viagra and related phosphodiesterase (PDE5) inhibitors
 - Psychopharmacologic meds

• Systemic Conditions

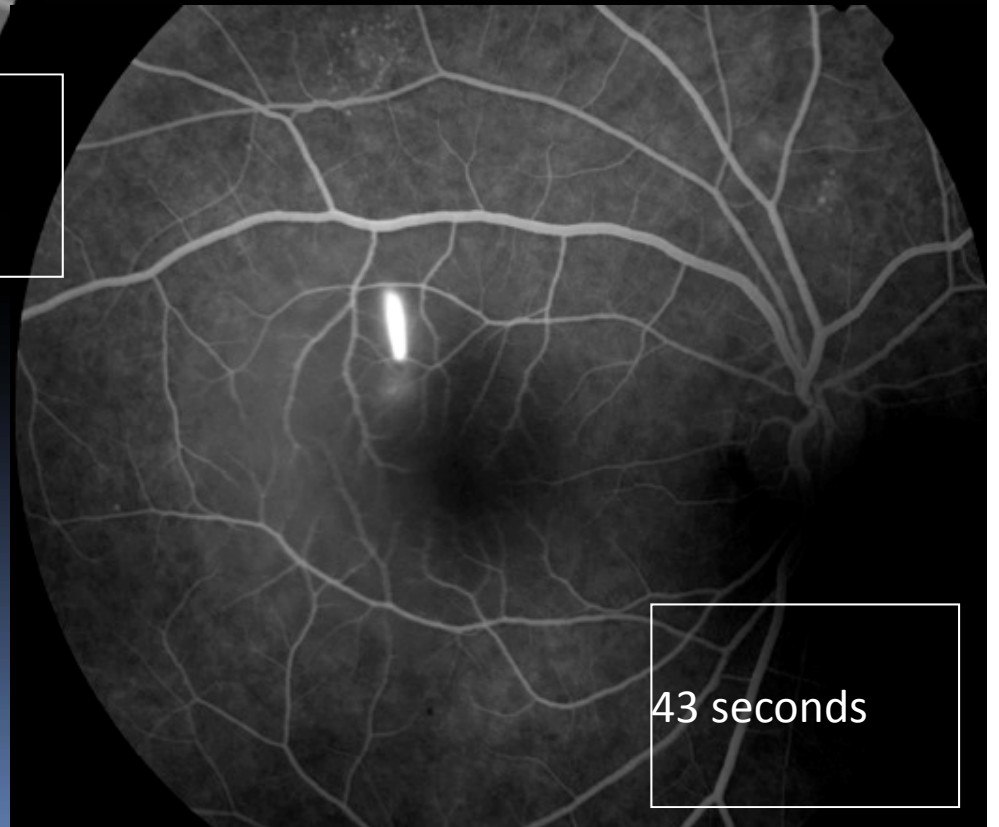
- Pregnancy
- HTN, ESRD, SLE & other autoimmune dz, transplant
- OSA – due to increased catecholamine levels and enhanced sympathetic activity
- H. Pylori – positive treatment effect seen for SRF resolution (no difference in VA)

CSCR Imaging: FA

- FA – not necessary for diagnosis, but needed to r/o entities on DDx
 - Classic smokestack (<10%, larger PEDs)
 - dye spreads vertically from the RPE

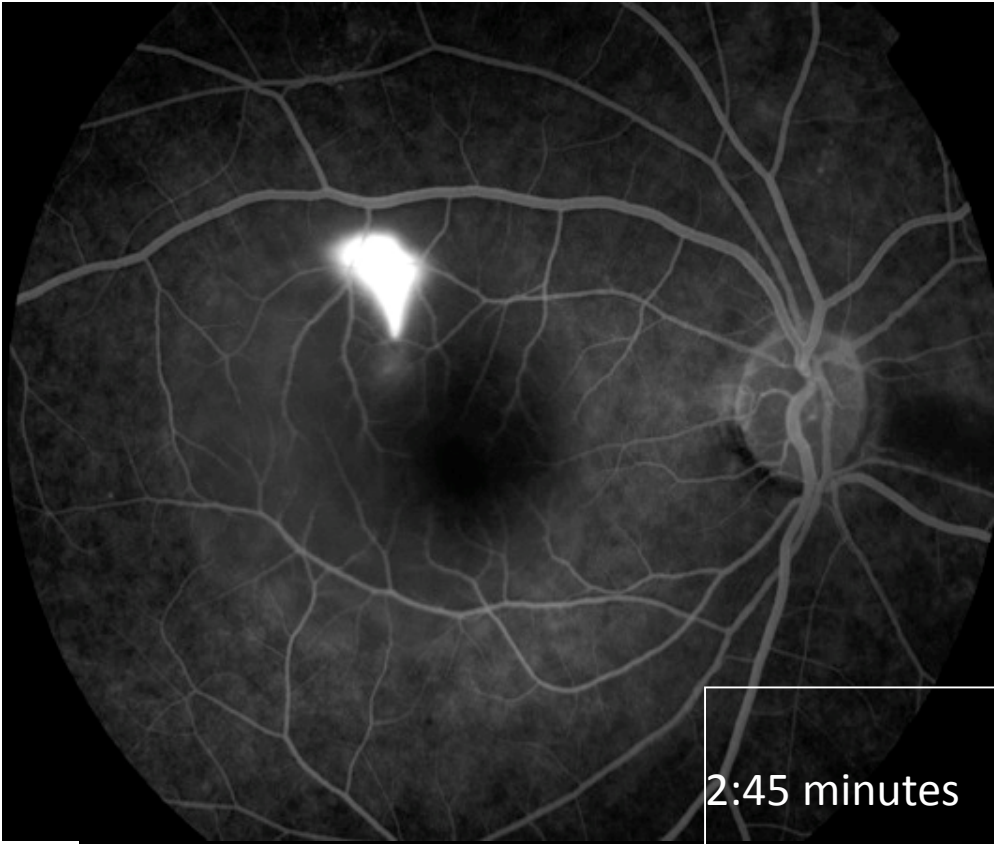


29 seconds

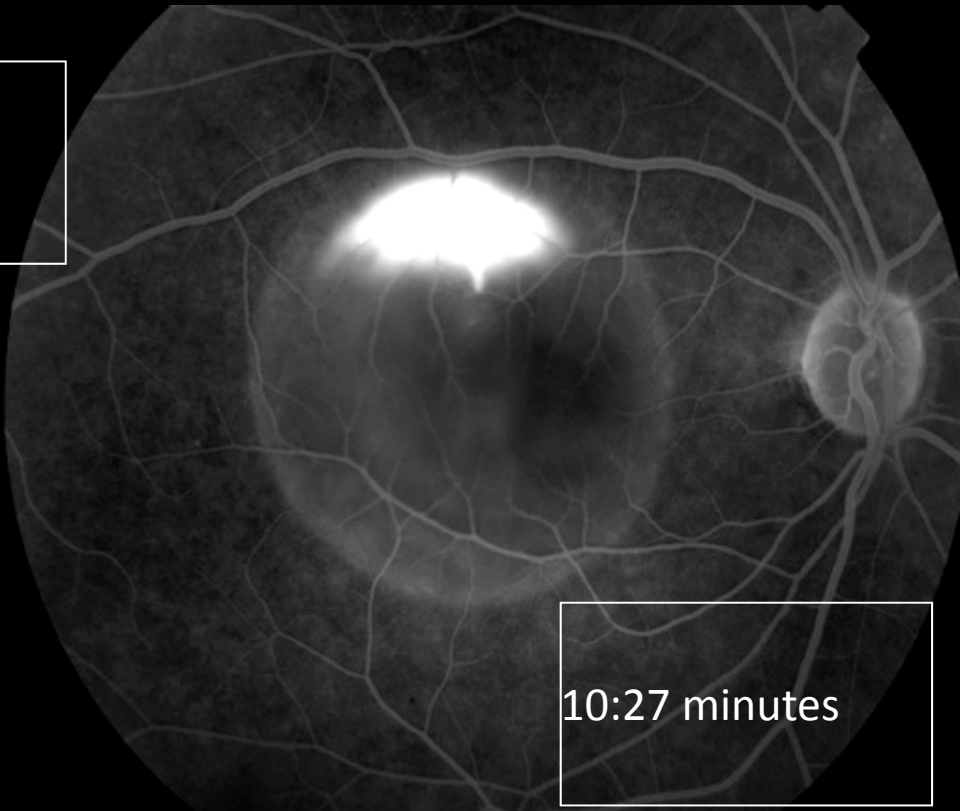


43 seconds





2:45 minutes

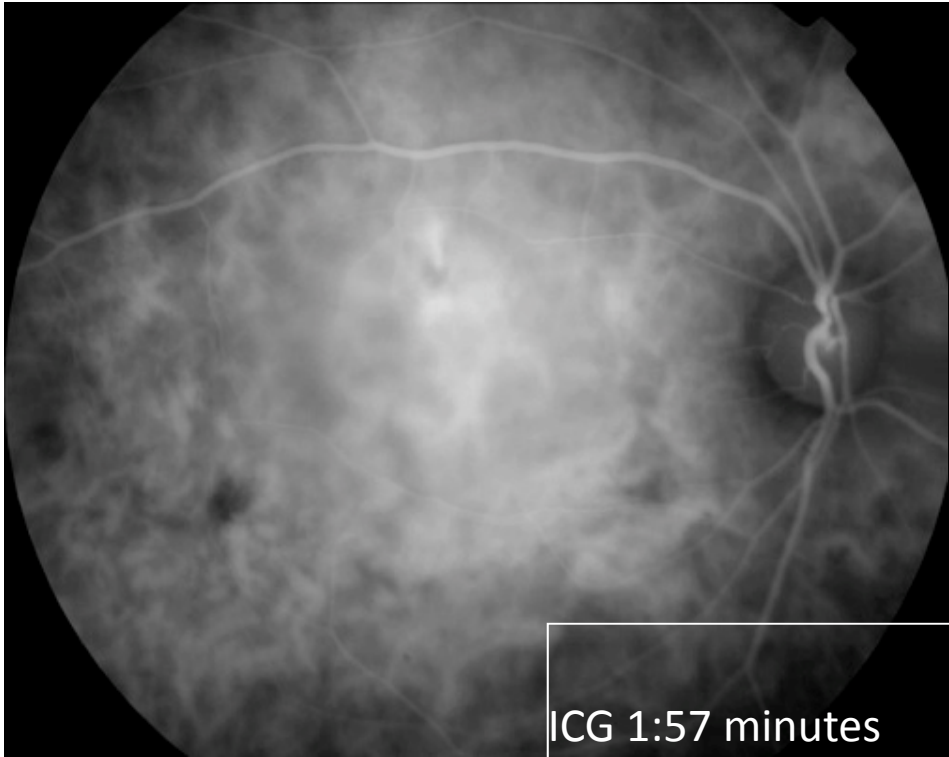


10:27 minutes

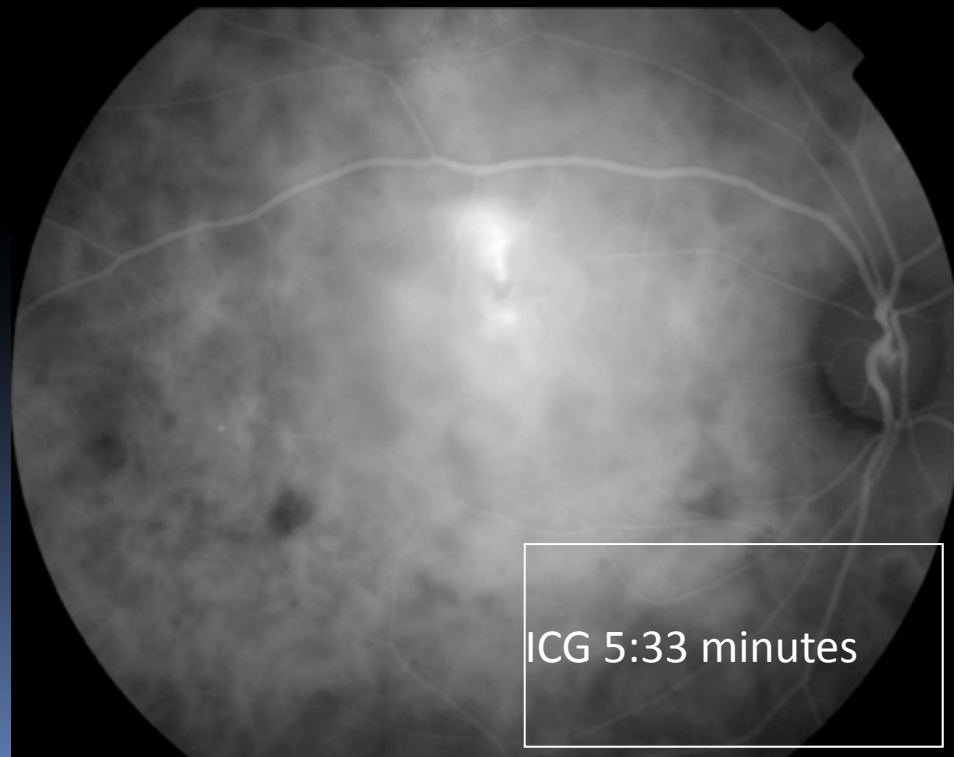


CSCR Imaging: ICG

- Choroidal lobular ischemia, and areas of choroidal vascular permeability
 - Hyperpermeability @ **areas of focal SRF** and elsewhere
 - Focal areas of hyperF also seen in fellow eyes
 - **Staining of choroidal vessels**, corresponds to areas of fibrin
 - Originates in choroid and extend into SRS via “blow-out” of RPE

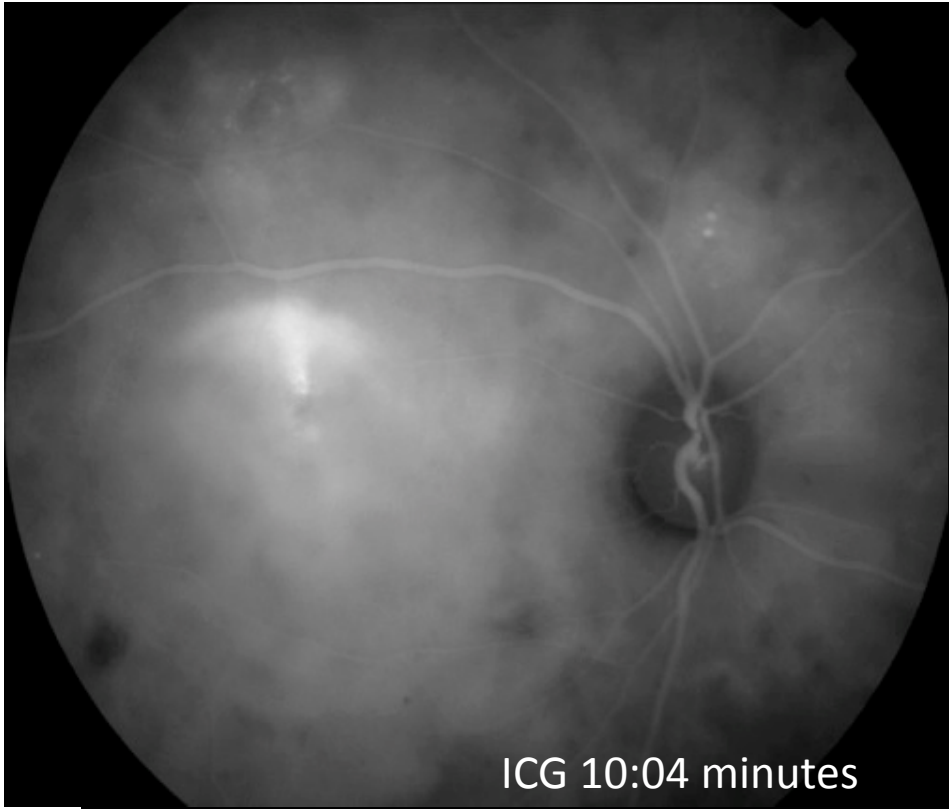


ICG 1:57 minutes

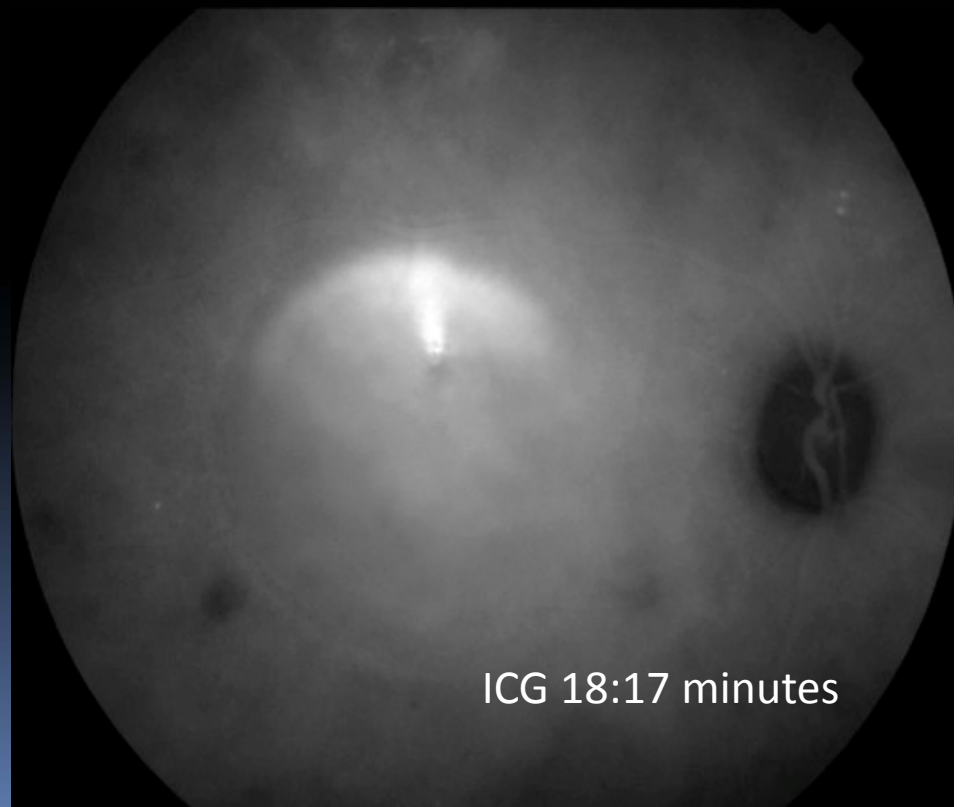


ICG 5:33 minutes





ICG 10:04 minutes

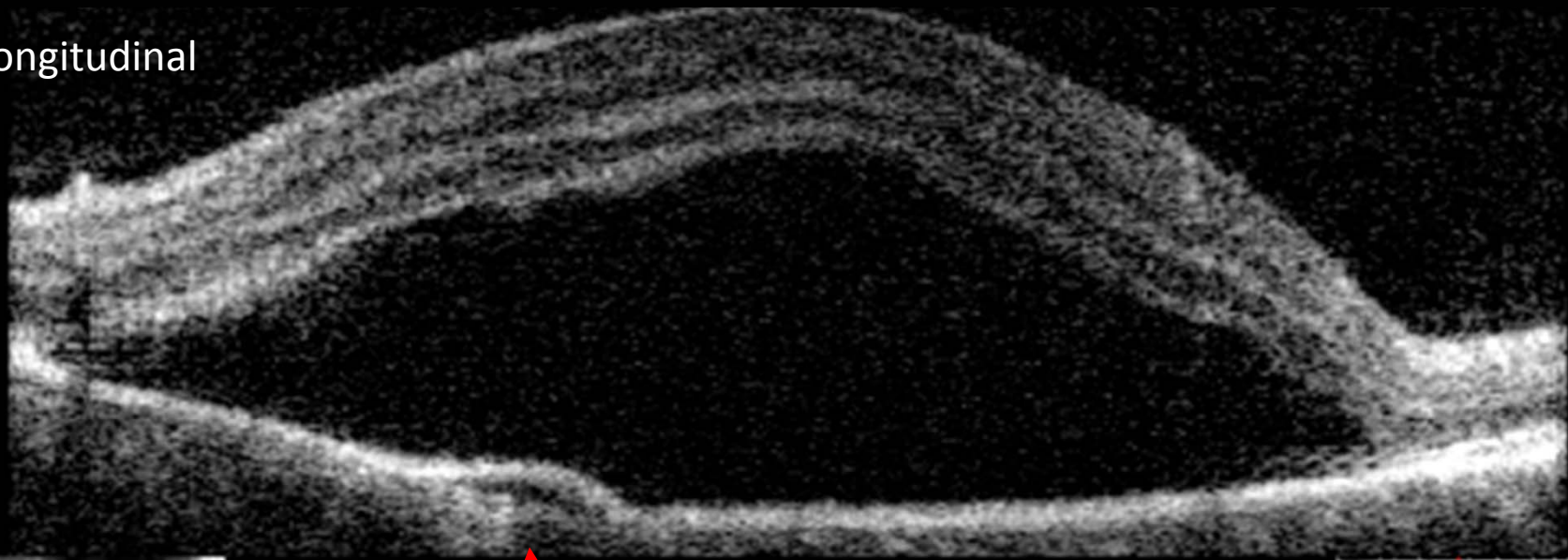


ICG 18:17 minutes

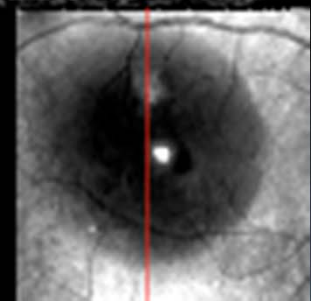



CSCR Imaging: OCT

Longitudinal

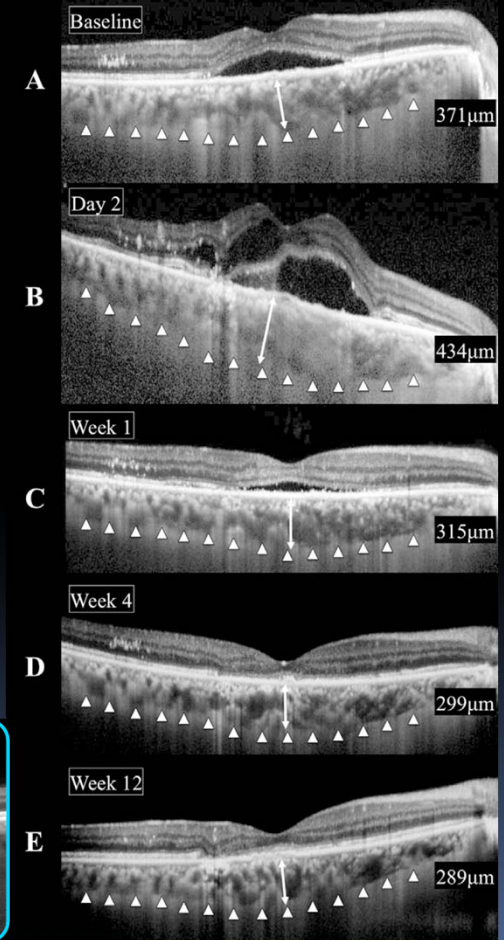
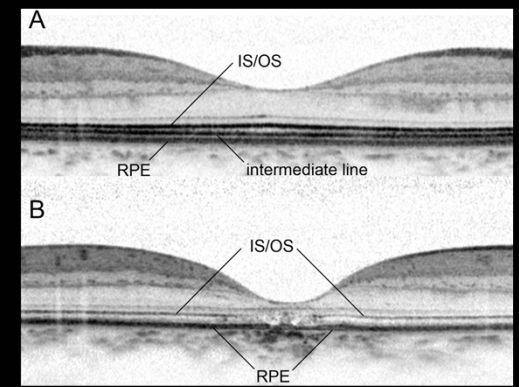


PED

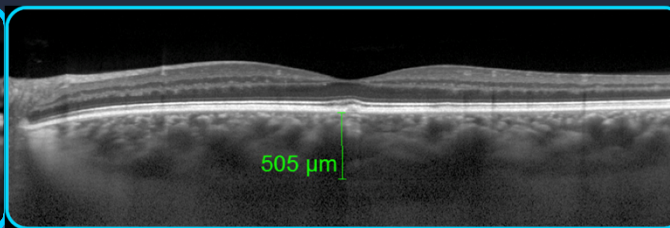



Newer Imaging Modalities: EDI OCT

- Conventional OCT – limited ability to image choroid
- IS/OS line disturbance
 - Represents integrity of outer photoreceptor layer
 - Eyes with resolved CSR but poor VA have no restoration of the IS/OS line
- Enhanced depth imaging OCT has been developed for choroid
 - Subfoveal choroidal thickness measured from outer surface of RPE → inner surface of sclera
 - Thickness decreases s/p half-fluence PDT

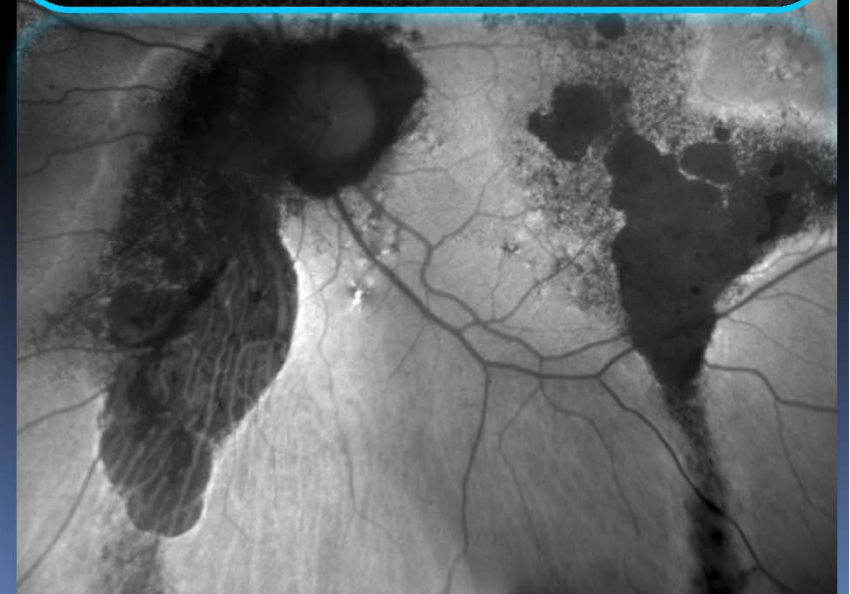
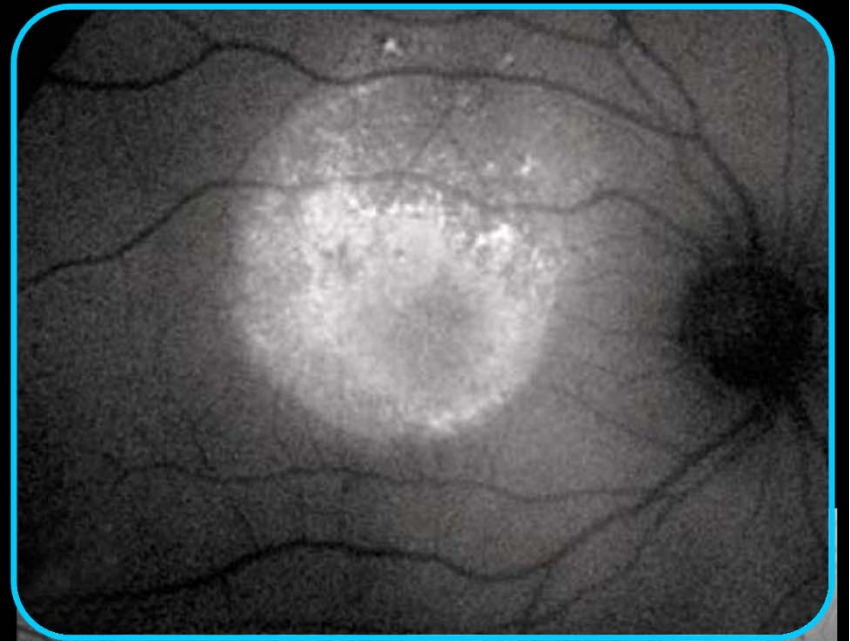

EDI: Normal Thickness



CSCR Imaging : AF

- Generally: PED is hyper-autofluorescent in acute CSR, and patchy in chronic
- Hypo-autofluorescent areas show dead cells



CSCR Prognosis & Management

- Prognosis and Management
 - Most patient undergo spontaneous resolution 1-6 months
 - Conservative management and steroid discontinuation is expected to be 90% successful in detachment resolution within 1.5mo
 - Mild residual symptoms - decreased central acuity/color vision, reduced contrast sensitivity and metamorphopsia
 - Rarely severe visual loss, chronic cases do worse
 - Recurrences 20-40%

CSCR Prognosis & Management

- PDT – to alter choroidal hyperpermeability and thicken BRB @ level of RPE
 - Both FA & ICG-guided PDT have been performed
 - **Low-fluence PDT currently recommended**, since less risk of ischemia
- Argon laser photocoagulation to site of leakage
 - Accelerates resolution of detachment
 - Currently used for **classic, extrafoveal CSR with obvious focal leaks on FA**, ineffective in chronic

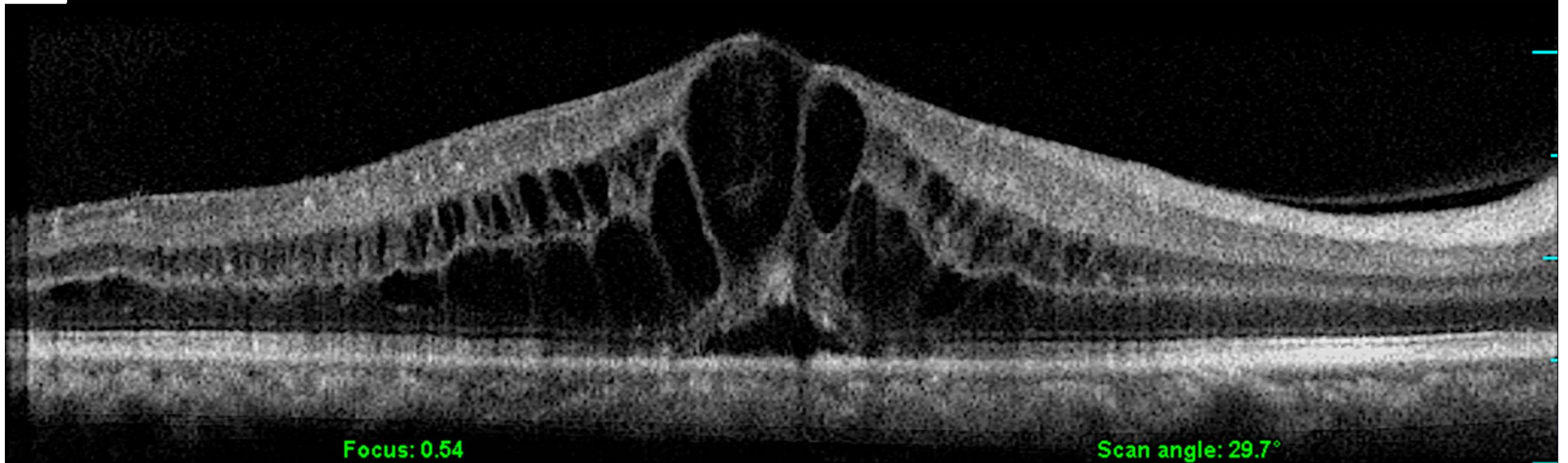
CSCR Treatment Criteria

- Laser photocoagulation may be considered if:
 - Persistence of serous detachment beyond 3-4 months
 - Recurrences in eyes with visual deficit from previous episodes (or fellow eye)
 - Occupational or other patient needs that require prompt restoration of vision/stereopsis
 - Development of chronic signs (cystic changes in the retina or widespread RPE abnormalities)

DDx CSCR

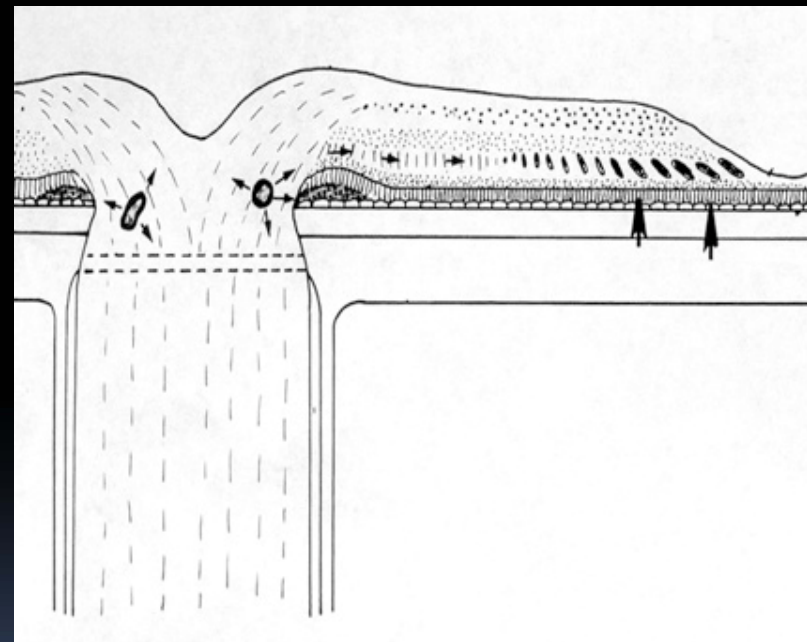
- Congenital optic disk pit
- Harada's disease
- PED (AMD)
- CNV
- Punctate inner choroidopathy (PIC)
- Best's disease

Cystoid Macular Edema CME



CME

- Accumulation of intra-retinal fluid in the macula with formation of cystoid spaces
 - Outer plexiform layer
 - Inner nuclear layer of the parafoveal retina
 - Coalescence into larger cavities may progress to lamellar hole
- Pathogenesis involves breakdown of blood-retinal barrier
 - Arachidonic acid pathway, which produces prostaglandins and leukotrienes implicated
- Associated with many conditions

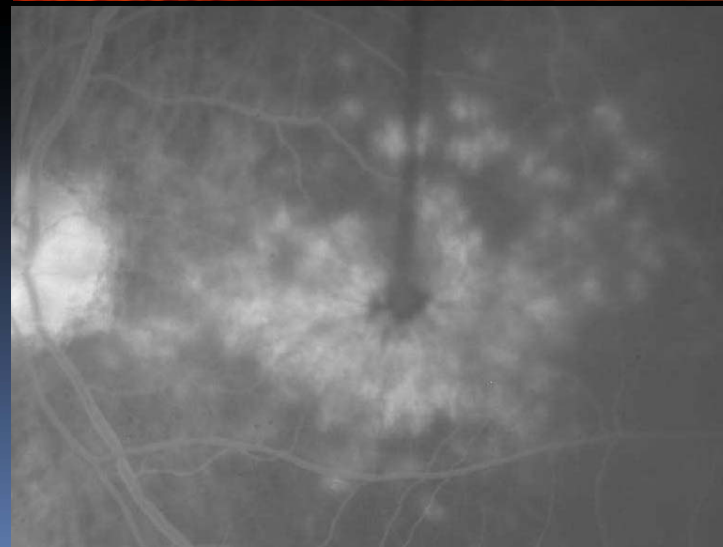
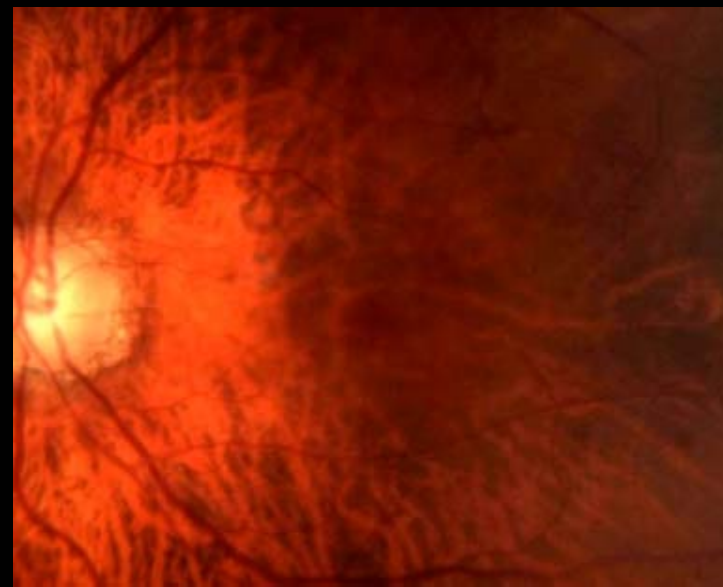


Conditions Leading to CME

- Post-cataract (Irvine-Gass)
- Uveitic
- Vasculopathy
 - Diabetic Retinopathy
 - Venous Occlusion
- Retinal dystrophies (CAI)
 - RP, gyrate atrophy, dominant CME, XLRS, Goldman-Favre, Usher's
- Drug-induced
 - PG derivatives, Epinephrine, PO glitazones, Niacine, Taxol, Nicotinic Acid
- Conditions involving VMT
- CNV, chronic disciform scar
- Fundus tumors
 - Melanoma, choroidal hemangioma, VHL
- Systemic disease
 - MM, Leukemia, CRF

CME Types

- **Clinical CME** implies visible cystoid spaces
- **Angiographic CME** implies leakage in the fovea, usually petalloid appearance
- **Clinically significant CME** means angiographic CME with symptoms (decreased vision)
- Incidence: angiographic CME, approximately 19% with phaco/IOL vs. clinically significant CME, 2-10%



CME Treatment

- No consensus; Options include:
- Topical NSAID's
 - Ketorolac (Acular) is FDA approved for post-operative CME
 - Nevanac is approved for "post-operative pain and inflammation associated with cataract surgery"
- Steroids (topical, ST, intra-vitreous), depends on etiology & response
 - No prospective clinical trial has proven efficacy
 - Not FDA approved for this purpose, but generally used
 - 75% of patients with intermediate uveitis and visual acuity of less than 20/40 have CME
 - Periocular steroids particularly effective
 - Watch out for steroid-induced glaucoma

CME Treatments

- Vitrectomy
 - To relieve traction from vitreous and remove cytokine-laden vitreous
 - Especially helpful if:
 - vitreous traction
 - iris capture of IOL
 - improperly placed or sized IOL
 - vitreous adhesion to anterior structures or to wound



Thank You & Good Luck!!